Effect of leaf extract and fractions of *Solanum anomalum* on oxidative stress markers, kidney function indices and histology of alloxan-induced diabetic rats

[1]Idongesit C. Etuk, [2]John A. Udobang, [3]Akaninyene O. Daniel,[3]Otuekong Ekong, *[1]Jude E. Okokon, [4]Oyepata Simeon Joseph

[1]Department of Pharmacology and Toxicology, Faculty of Pharmacy, University of Uyo, Uyo, Nigeria.
[2]Department of Clinical Pharmacology and Therapeutics, Faculty of Basic Clinical Sciences, University of Uyo, Uyo, Nigeria.
[3]Department of Pharmaceutical and Medicinal Chemistry, Faculty of Pharmacy, University of Uyo, Uyo, Nigeria.
[4]Department of Pharmacology, Faculty of Pharmaceutical Sciences, Federal University, Oye - Ekiti State, Nigeria.

Submitted: 6th Oct., 2022; Accepted: 19th Feb., 2023; Published: 28th Feb., 2023
DOI: https://doi.org/10.54117/jcbr.v3i1.4
**Corresponding author:* judeefiom@yahoo.com; +234-8023453678

Abstract
In ethnomedicine, the leaf of *S. anomalum* is used to treat a variety of illnesses, including diabetes. The goal of this study was to assess the effects of *S. anomalum* leaf extract and fractions on the kidney function indices, renal histology, and indicators of oxidative stress in rats with diabetes caused by alloxan. Antioxidative stress and renoprotective potentials of leaf extract (70-210 mg/kg) and fractions (140 mg/kg) were assessed by determining oxidative stress markers levels, kidney function parameters and histopathology of alloxan-induced diabetic rats. The levels of oxidative stress indicators (Superoxide dismutase (SOD), Catalase (CAT), Glutathione peroxidase (GPx), and glutathione (GSH) in the kidney were significantly increased by the leaf extract and fractions ($p<0.05–0.001$), while the level of MDA was lowered in the treated diabetic rats. The high serum levels of urea and creatinine in diabetic rats were significantly ($p<0.05–0.001$) reduced by the leaf fractions, whereas the levels of electrolytes were not significantly decreased . The kidney histology of the treated diabetic rats either showed no pathological abnormalities or a considerable reduction in pathological features. The findings suggest the antioxidative stress and nephroprotective capabilities of *Solanum anomalum* leaf extract and fractions, which may be a result of the antioxidant activities of their phytochemical constituents.
Keywords: *Solanum anomalum*, medicinal plant, kidney protective, antioxidant, antioxidative

Introduction

Diabetes mellitus is a chronic metabolic condition characterised by an increased production of free radicals, particularly ROS (Okutana *et al.*, 2005). According to Matthews and Leiter (1999), the body's conversion of alloxan to dialuric acid is accompanied by the production of H2O2, •OH, and superoxide radicals via an iron catalyst. These radicals damage organs like the kidney, liver, and pancreas, among others, and are linked to the pathogenesis of diabetes complications in both animals and humans (Baynes and Thorpe,1999). Through covalent binding, DNA strand breakage, lipid peroxidation, and enhancement of fibrosis(which is also linked to other disease conditions),reactive oxygen species (ROS) cause cellular and

tissue harm (Paradies *et al.*, 2011). Medicinal plants that have historically been used to manage diabetes can be standardized as antidiabetic regimen that could be safer than the available antidiabetic agents.

A common plant in the subregions of West and East Africa called *Solanum anomalum* Thonn. ex Schumach is used for food and medicine. Its fruits are edible. Its parts are used locally in ethnomedicine to treat conditions like diabetes, gastrointestinal problems, infections, inflammation, and pain (Burkill, 2000; Bukenya and Hall, 1988; Offor and Ubengama, 2015). It has been reported that the fruits and leaves of the plant have hypoglycemic and anti-diabetic properties (Offor and Ubengama, 2015; Okokon e*t al.*, 2022). More specifically the leaf extract has exhibited *in vivo* and *in vitro* antiplasmodial activity (Okokon et al., 2016; Okokon *et al.*, 2017a). Its anti-oedema (Okokon *et al.*, 2017b), antidiarrhoeal (Udobang *et al.*, 2022), antinociceptive (Okokon *et al.*, 2020), antioxidant and antiulcer (Okokon *et al.*, 2019a), anticonvulsant and depressant (Okokon *et al.*, 2019b) activities have also been reported . The leaves have been found to contain alkaloids, flavonoids, saponins, tanins, diosgenin, a diosgenin glycoside (25(R)-diosgenin-3-O—L-rhamnopyranosyl-(14)—D-glucopyranoside), uracil, 5-methyluracil, 1-octacosanol, and octacosane (Okokon *et al.*, 2016; Okokon *et al.*, 2022). In this study, the antioxidative stress and nephroprotective properties of leaf extract and plant fractions of *S. anomalum* in the presence of alloxan-induced kidney damage was investigated.

Materials and Methods

Plants collection

In August 2022, fresh leaves of *Solanum anomalum* were gathered in compounds in the Uruan area of Akwa Ibom State, Nigeria. A taxonomist (Prof. Margaret Bassey) from the Department of Botany and Ecological Studies at the University of Uyo in Uyo, Nigeria, identified the plant. The Department of Pharmacognosy and Natural Medicine Herbarium at the University of Uyo received the hebarium specimen (UUH.75a).

Extraction

S. anomalum fresh leaves were washed, cut into smaller pieces, and allowed to dry for two weeks in the shade. With the aid of an electric grinder, the leaves were further ground into powder. The powdered leaves material (1.5 kg) was macerated in 7.5 L of 50% ethanol for 72 hours at room temperature (28 °C). After filteration, the liquid filtrate was concentrated and evaporated to dryness using a rotary evaporator(BuchiLab, Switzerland) in vacuo at 40°C. The extract was kept in a refrigerator at a temperature of -4 °C until when it was needed.

Animals

Wistar albino rats (138-150 g) of either sex were obtained from the University of Uyo animal house. They were maintained on standard animal pellets and water *ad libitum*. Permission and approval for animal studies were obtained from the College of Health Sciences Animal Ethics committee, University of Uyo.

Induction of experimental diabetes using alloxan monohydrate

Sixty (60) healthy albino Wistar rats (male and female) of known weights were fasted for 24 hours, they were reweighed before diabetes was inducted by a single intraperitoneal injection of freshly prepared solution of alloxan monohydrate (150 mg/kg) in ice cold 0.9% saline (NaCl solution). The animals were given 2 mL of 5% dextrose solution immediately after induction to overcome the initial hypoglycaemia (Pari and Saravanan, 2002),. The animals were allowed to rest for 72 h and allowed access to food and water to enable diabetes to be fully developed during this

period. After the rest period, rats with moderate diabetes, having persistent glycosuria, and hyperglycaemia (i.e with blood glucose levels 200 mg/dL and above), (Lenzen, 2008) were considered diabetic and selected for the experiments.

The diabetic animals were randomly assigned to nine (9) experimental groups, each containing six rats. Following the selection of optimal dose regimens based on the value of the previously established median lethal dose (LD_{50}) (Okokon *et al.*, 2022), the rats were administered the following treatments. Group 1 received 10 mL/kg/day of normal saline orally, group 2 received 5 mg/kg/day of glibenclamide orally, group 3 received 70 mg/kg/day of *S. anomalum* leaf extract orally, group 4 received 140 mg/kg/day of the extract orally while group 5 received 210 mg/kg/day of the extract respectively. The n-hexane, dichloromethane, ethyl acetate, and methanol fractions of *S. anomalum* leaves (140 mg/kg) were given orally to groups 6,7,8 and 9 for 14 days respectively.

Effect of administration of leaf extract and fractions of *S. anomalum* on fasting blood glucose of alloxan-induced diabetic rats.

Following the administration of the leaf fractions for 14 days, the fasting blood glucose (FBG) levels of all the rats were assessed. "The tail-tipping method" was the technique used. Rat tail vein blood was drawn, and the dextrostix reagent pad was placed on top. The pad was then placed inside a microprocessor digital blood glucometer, and values were recorded (WHO, 1980).

In order to generate the appropriate fasting period for the measurement of the fasting blood glucose concentrations, food was withheld from the experimental animals 12 hours before the measurement of FBG for all treatments throughout the course of the experiment.

Determination of the body weights changes of the treated diabetic rats

The body weights o the animals monitored and recorded throughout the experiment: just before fasting to prepare for diabetes induction, after diabetes induction to ensure stability, and after the prolonged study period of 14 days.

Collection of blood samples and organs

After 14 days of treatment (24 hours after the last administration) the rats were weighed again and sacrificed under light diethyl ether vapour. Blood samples were collected by cardiac puncture and used immediately. Blood were collected into plain centrifuge tubes. The blood in the centrifuge tubes were allowed to stand for 30 mins and centrifuged at 1500 rpm for 15 mins to separate the serum at room temperature and used for biochemical assays. The kidneys of the diabetic rats were surgically removed, weighed and one kidney from each rat was fixed in 10% formaldehyde for histological process.

Biochemical Analysis
Kidney Function Test

The amounts of electrolytes (Na, K, Cl, and HCO3), creatinine, uric acid, and urea were determined and used as indices of renal function using Fortress Diagnostic Kits® (Fortress Diagnostic Limited,UK) according to standard procedures of manufacturer's protocols at the Chemical Pathology Department of University of Uyo Teaching Hospital, Uyo.

Preparation of renal homogenate

Each kidney removed from the rats was separated from the fat and connective tissue around it and dissected. The renal cortex of each kidney was isolated and maintained at 8°C after being longitudinally sectioned. A cold potassium phosphate buffer was then

used to homogenize the renal cortex (0.05 M, pH 7.4). Centrifuging was done on the renal cortical homogenates at 5000 rpm for 10 minutes at 4°C. The resultant supernatant was used to measure the malondialdehyde (MDA) level and superoxide dismutase (SOD), catalase (CAT), glutathione peroxidase (GPx), and reduced glutathione (GSH) activities using a colorimetric test (Ellman, 1959; Esterbauer and Cheeseman, 1974; Marklund and Marklund, 1974; Sinha, 1972; Lawrence and Burk, 1976).

Statistical analysis

Data obtained from this work were analysed statistically using ANOVA (one –way) followed by a post-test (Tukey-Kramer multiple comparison test). Differences between means were considered significant at 5% and 0.1% level of significance ie $p \leq 0.05$ and 0.001.

Results

Effect of leaf extract and fractions on body weights of rats

The body weight of the diabetic rats increased after treatment with the leaf extract and fractions in a non-dose dependent manner, with the intermediate dose (140 mg/kg) producing the greatest weight gain. These increases were largest in the medium dosage treated group (10.02%), followed by the methanol fraction-treated group (8.77%), and were significant ($p<0.05–0.001$) when compared to control. (Table 1).

Effect of extract and fractions on weights of kidney

The weights of the kidneys of the diabetic rats, treated with the leaf extract and fractions of *S. anomalum* decreased non-dose dependently. These reductions were not statistically significant ($p<0.05$) as compared to the control group.

Antidiabetic activity of the leaf extract and fractions during prolonged treatment

Following repeated administration, the leaf extract caused reductions in FBG levels in the diabetic rats that were statistically significant ($p<0.05–0.001$). These effects were similar to that of standard drug, glibenclamide. Day 14 results for 70, 140, and 210 mg/kg and glibenclamide were 64,08%, 63.43%, 65.43%, and 64.54%, respectively (Table 1). The different fractions administration resulted in sustained significant ($p<0.05$-0.001) decreases in the diabetic rats' FBG. Day 14 results for the fractions; n-hexane, dichloromethane, ethyl acetate, and methanol, were 67.99, 54.66, 66.08, and 66.77%, respectively. The effects of *n*-hexane, ethyl acetate, and methanol were comparable to that of the standard drug, glibenclamide. (Table 1).

Effect of leaf extract and fractions on kidney function parameters of diabetic rats

When compared to controls, the diabetic rats showed considerably lower serum levels of creatinine, urea, and uric acid after receiving leaf extract and fractions of *Solanum anomalum*, with methanol, ethyl acetate, and hexane fractions having the most significant ($p>0.05$-0.01) effects. When compared to the control group, the levels of bicarbonate, chloride, sodium, and potassium in the extract/fractions-treated groups were not substantially different ($p>0.05$). (Table 2)

Effect of leaf extract and fractions on kidney antioxidant enzymes

When compared to the control group, the administration of *S. anomalum* leaf extract and fractions significantly ($p>0.05$-0.001) increased kidney antioxidant enzymes' activities (SOD, GPx, CAT), and GSH levels, with the DCM fraction-treated group

having the greatest values. The treatment also resulted in a significant ($p<0.001$) lower level of MDA in the diabetic rats, with the DCM fraction having the greatest impact. (Table 3).

Table 1: Effect of leaf extract and fractions of *Solanum anomalum* on body and Kidney weights of alloxan- induced diabetic rats.

TREATMENT	**DOSE**	**BODY WEIGHT (g)**			**WEIGHTS OF kidney (g)**	**FASTING BLOOD GLUCOSE (mg/dl)**	
	mg/kg	Day 0	Day 15	% Increase		0 HR	14TH DAY
Control normal saline	-	132.6 ± 18.34	129.3± 20.43	-2.48	1.48±0.02	266.0±17.16	249.0±14.01
Glibenclamide	10	132.0 ± 9.45	141.3± 12.33	7.04	1.21±0.03	233.0±12.00	82.6±8.19[b]
Extract	70	143.6 ± 12.55	158.0 ± 3.15	10.02	1.14±0.14	279.3±14.74	100.3±16.69[b]
	140	152.8 ± 15.56	163.0± 9.29	6.67	1.18±0.06	260.6±8.32	95.3±11.29 [a]
	210	140.8 ± 13.29	152.6 ± 7.22	8.38	1.37±0.28	257.0±3.71	88.3±8.83[b]
n- hexane fraction	140	142.9 ± 8.54	153.6 ± 6.48	7.48	1.27±0.07	264.3±14.50	84.6±40.05[c]
Dichloromethane fraction	140	138.4 ± 6.26	144.6± 13.71	4.68	1.10±0.03	236.0±37.60	107.0±14.52[b]
Ethyl acetate fraction	140	144.31 ± 8.50	156.6± 9.88	8.51	1.27±0.04	271.3±13.04	92.0±14.29[a]
Methanol fraction	140	145.8 ± 7.45	158.6± 10.55	8.77	1.13±0.08	245.6±12.33	81.6±18.49[b]

Data is expressed as MEAN ± SEM, Significant at [a]$p<0.05$, [b]$p< 0.01$, [c]$p< 0.001$, when compared to control. (n=6).

Table 2: Effect of *S. anomalum* leaf extract and fractions on renal function parameters of alloxan-induced diabetic rats

TREATMENT	DOSE (mg/kg)	CREATININE (mg/kg)	UREA (mg/dl)	URIC ACID (mg/dl)	BICARBONATE (mMol/L)	SODIUM (mMol/L)	POTASSIUM (mMol/L)	CHLORIDE (mMol/L)
Control normal saline	10 mg/ml	68.96± 1.01	11.73± 1.50	0.19±0.03	25.66± 1.20	146.3±1.33	6.00± 0.20	103.0± 0.00
Crude extract	70	55.96± 0.86	10.33± 1.50	0.09± 0.01[c]	27.66± 1.85	147.6±3.18	5.76± 0.08	102.0± 1.20
	140	66.66± 7.92	9.66± 0.58	0.18± 0.05	27.50± 2.50	146.0± 0.57	5.50± 0.17	101.0± 1.52
	210	55.83±2.48[a]	7.70± 0.85[a]	0.13± 0.03	26.75±1.10	144.0±1.00	6.06± 0.40	99.0± 1.52
***n*-hexane fraction**	140	64.90± 8.90	10.16± 3.65	0.14±0.06	29.00± 1.68	143.0±1.00	5.76± 0.27	97.3± 1.45
Dichloromethane fraction	140	53.53± 2.24[a]	9.10± 1.13	0.09± 0.01[c]	30.25± 0.75	144.0± 0.57	5.36± 0.21	99.0± 1.15
Ethyl acetate fraction	140	57.90± 1.57	7.40± 1.62[a]	0.15±0.01	29.66± 0.88	144.3± 0.33	5.56± 0.21	100.0± 0.57
Methanol fraction	140	55.10± 0.58 [a]	6.63± 0.09 [a]	0.08±0.03[c]	32.80± 1.67	144.3± 2.02	5.56± 0.17	99.66±1.76
Glibenclamide	10	55.20±1.12[a]	7.96± 1.69[a]	0.16±0.03	27.66± 1.20	141.6± 1.20	4.53± 0.08	99.66± 1.20

Data is expressed as MEAN ± SEM, Significant at [a]p<0.05, [b]p< 0.01, [c]p< 0.001, when compared to control. (n=6).

Table 3: Effect of *S. anomalum* leaf extract on kidney antioxidative stress markers in alloxan-induced diabetic in rats.

PARAMETERS/ TREATMENT	**Dose mg/kg**	**SOD (µg/mL)**	**CAT (IU/L)**	**GST (µg/mL)**	**GSH (µg/mL)**	**GPx (µg/mL)**	**MDA (µMol/mL)**
Control normal saline	10 mg/ml	0.37± 0.04	0.49± 0.05	0.016±0.008	0.86±0.07	0.045±0.001	0.38±0.06
Crude extract	70	0.40± 0.01	0.62± 0.04	0.037±0.006^{c}	0.87±0.06	0.049±0.003	0.36±0.02
	140	0.52± 0.01^{a}	0.93±0.26^{c}	0.067±0.001^{c}	1.06±0.04^{c}	0.051±0.001	0.26±0.05^{a}
	210	0.46± 0.01	0.76±0.04^{c}	0.064±0.001^{c}	1.07±0.15^{c}	0.052±0.001	0.30±0.01
n-hexane fraction	140	0.51±0.02^{a}	1.63±0.53^{c}	0.055±0.001^{c}	0.95±0.01^{a}	0.053±0.005^{a}	0.23±0.02^{b}
Dichloromethane fraction	140	0.62±0.02^{c}	1.19±0.30^{c}	0.087± 0.001^{c}	1.02±0.02^{c}	0.054±0.001^{a}	0.18±0.02^{c}
Ethyl acetate fraction	140	0.52±0.02 ^{a}	0.84±0.17^{c}	0.060±0.008^{c}	0.92±0.05	0.044±0.002	0.27±0.01^{a}
Methanol	140	0.54± 0.02^{a}	0.83±0.36^{c}	0.046±0.004^{c}	1.05±0.02^{c}	0.048±0.001	0.24±0.01^{b}
Glibenclamide	10	0.46± 0.05	0.91±0.30^{c}	0.046±0.008^{c}	1.03±0.02^{c}	0.048±0.001	0.26±0.01^{a}

Data were expressed as mean ± SEM. significant at ap< 0.05, bp< 0.01, cp< 0.001 when compared to diabetic control. n = 6.

Effect of extract and fractions on the histology of kidney of diabetic rats

The kidneys of untreated diabetic rats underwent histologic analysis, which revealed areas of glomerular inflammation, vascular obstruction, cellular degeneration, severely dilated renal tubules with degenerated epithelium and flattened cell, tubular epithelial hyperplasia, atrophic glomeruli (GMa), renal tubular hyperplasia, severely dilated tubules with degenerated epithelium evidence with only flattened cell, few (V). These degenerative symptoms were particularly evident in diabetic rats that were left untreated; however, extract and glibenclamide treatment reduced these signs, while DCM and ethyl acetate treatment groups resulted in kidneys with normal cytoarchitecture and extract-treated rats with normal kidney function (x400) (Figure 1A-9A).

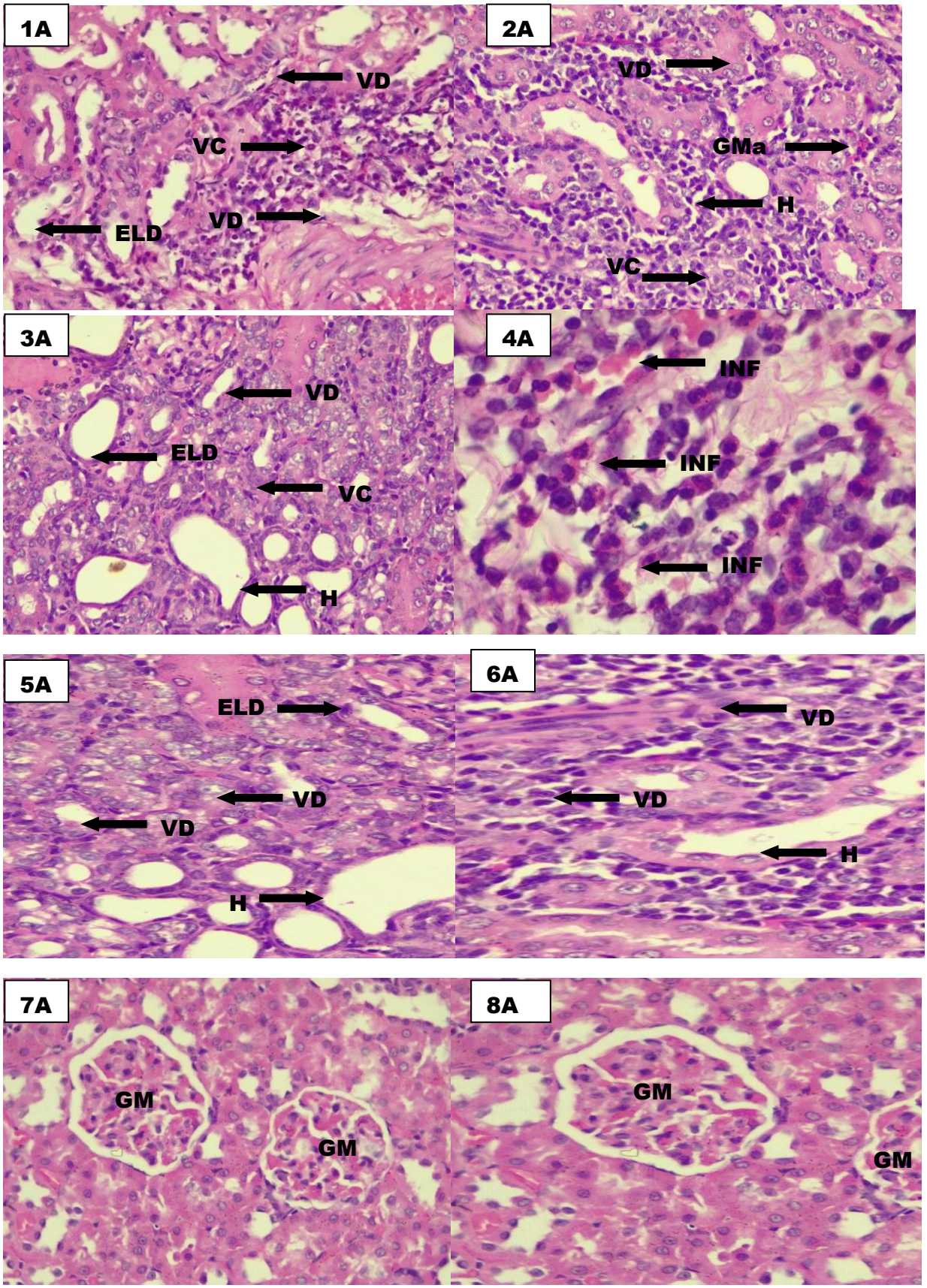
1A
VD
VC
ELD
VD
2A
VD
GMa
H
VC
3A
VD
ELD
VC
H
4A
INF
INF
INF
5A
ELD
VD
VD
H
6A
VD
VD
H
7A
GM
GM
8A
GM
GM

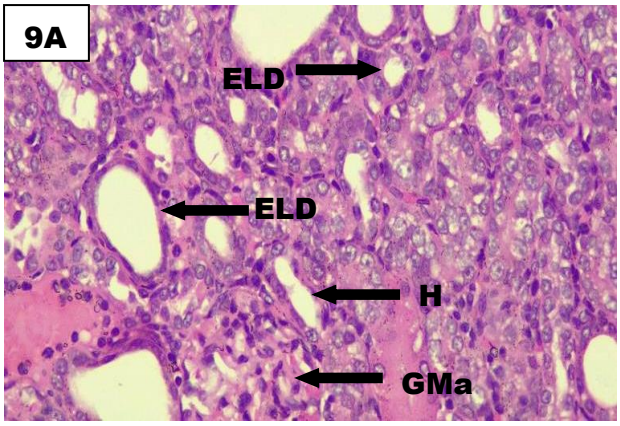

Figure 1: Histological sections of Kidneys of alloxan-induced diabetic rats treated with Normal saline 10 mL/kg(1), Glibenclamide 10 mg/kg bw (2), leaf extract 70 mg/kg bw (3), leaf extract 140 mg/kg bw (4), leaf extract 210 mg/kg bw (5), n-hexane fraction 140 mg/kg (6) dichloromethane fraction 140 mg/kg (7), ethyl acetate 140 mg/kg (8), methanol fraction 140 m/kg (9), at Magnification A(x400), stained with H&E Method.

Keys: Vascular degeneration (VD), Glomerulus (**GM**), Glomerulus atrophy (**GMa**), Epithelial lining degeneration (**ELD**), vascular degeneration **(VD),** Hyperplasia (**H**), Inflammation (**INF**),

Discussion

The body weights of diabetic rats were found to increase significantly following treatment with the leaf extract and fractions especially at low dose, 70 mg/kg, methanol and ethyl acetate fractions. Induction of diabetes in rats with alloxan is associated with the characteristic loss of body weight, which is due to increased muscle wasting and due to loss of tissue proteins (Shirwaikar *et al.,* 2005). Treatment with the leaf fractions remedied this situation perhaps due to the chemical constituents of these fractions which have the ability to reduce hyperglycaemia by increasing glucose metabolism, inhibition of α-amylase and α-glucosidase enzyme, stimulation of protein synthesis and by controlling muscle wasting through reversal of gluconeogenesis(Singh *et al.,* 2007).

The leaf extract and fractions were observed in this study to cause significant decrease in the weight of the kidney of the treatment group compared to the diabetic untreated rats. Generally, the weight of internal organs are considered as important indicator to injury and toxicities (Farah *et al.,* 2013). Hypertrophy of organs often indicates toxicity and damage to organs (Ping *et al*., 2013). This often results from inflammation-induced oedema of the organs. Free radicals generated during alloxan metabolism cause destruction of hepatic, pancreatic and kidney cells and tissues (Mathews and Leiter, 1999). The decrease in weights of kidney by the extract/fractions especially DCM and methanol fractions-treated group, is as a result of protective effect of the fractions against the effect of free radicals generated by alloxan and diabetic condition. This protection could be ascribed to the hypoglycemic and antioxidant activities of the phytoconstituents (Okokon *et al.,* 2019a) such as diosgenin, 1-octacosanol, octacosane and β-sitosterol (Gupta et al., 2011; Baskar *et al.,* 2012;Kanchan *et al*., 2016;Leng *et al*., 2020; Sengupta *et al*., 2018; Rhetso *et al.,* 2018) and phenolic compounds in the leaf extract.

In addition, diosgenin a steroidal saponin, which is also present in *S. nigrum*,(Desai *et*

al., 2015; Herble *et al.,* 1967) has been isolated from the *n*-hexane fraction of the leaf extract under study. This compound is known to exert prominent antidiabetic activity in many studies (Pari *et al.,* 2012; Saravanan *et al.,* 2014; Roghani-Dehkordi *et al.,* 2015). Similarly, squalene and β-sitosterol also present in the extract exert antidiabetic activity (Gupta *et al.,* 2011; Ramu *et al*., 2016;Ivorra *et al.,* 1988;Widyawati*et al*., 2018). Their antioxidant activities against the free radicals generated by alloxan could have contributed to the observed activities in this study.

S. anomalum leaf extract/fractions were observed to exhibit sustained and significant antidiabetic activities during prolonged study with the methanol, n-hexane and ethyl acetate fractions. The fasting blood glucose (FBG) levels of the treated diabetic rats were significantly reduced when compared to those of untreated diabetic rats (control). The antidiabetic results observed in this study corroborate that of other species of *Solanum* such as *S. nigrum* (Sengottaiyan *et al.,* 2012; Umamageswari *et al*.,2017), *S. trilobatum* (Doss *et al.,* 2009), *S. xanthocarpum* (Selvi and Yogananth, 2016) and *Solanum villosum*(Nyaga *et al.,* 2019). Thus, confirming strongly the antidiabetic potentials of this plant in ethno medicine.

Slight reductions in the levels of chloride, potassium and sodium and insignificant increases in bicarbonate concentration in the serum were observed following treatment with the leaf extract and fractions. These redcutions were not significant at $p<0.05$.These effects could have resulted from the renoprotective activities of the extract/fractions against the effect of diabetes through the reduction of diabetic acidosis that usually leads to increased retention of sodium in the serum and decreased excretion of potassium in urine (Nduka, 1997). The leaf extract and fractions treatment could also have enhanced blood and urine glucose clearance, thereby suppressing water loss (dehydration) and ketoacidosis stimulus, thereby protecting the kidney.

The serum levels of urea, uric acid and creatinine in the extract and fractions treated rats were significantly reduced compared to the untreated rats especially at the dose of 210 mg/kg of the extract and in methanol, DCM and ethyl acetate fractions-treated groups. Diabetic condition results in high urea levels in diabetic rats due to insulin deficiency and inability of glucose to reach extra-hepatic tissue (Robinson and Johnson, 1997). The extract/fractions treatment must have enhanced the clearance of glucose from the blood and stimulated insulin secretion thereby reducing proteolysis, and subsequently, urea concentration in blood. Similar decrease was observed in creatinine level following treatment with the leaf extract and fractions. Creatinine is a metabolite of muscle creatine, whose amount in serum is proportional to the body's muscle mass. Elevated levels of serum creatinine indicate diminished renal function, as it is excreted by the kidney (Loeb,1991). The observed decrease in creatinine concentrations in this study suggest a protection of the kidney against damage by the herbal treatments.. The protective activities of the extract and fractions observed in this study is attributable to its constituent (diosgenin) which has been reported to possess kidney protective potential (Jain *et al.,* 2020; Kanchan *et al.,* 2016). These results compare well with the histologic findings which had demonstrated significant kidney protective effects and similar to renoprotective potential which was reported for *S. nigrum* (Mirunalini *et al.,* 2012; Dasgupta *et al*., 2016).

The leaf extract and fractions protected the kidneys of diabetic rats from alloxan-induced oxidative stress based on observation. Glomerular inflammation,

vascular congestion and cellular degeneration found in the untreated diabetic rats were absent in the kidneys of leaf fractions-treated rats. This suggests significant kidney protective effect. Dialuric acid, a metabolite of alloxan is known to generate free radicals which attack organs such as the kidney (Dixit and Kar, 2010).

The results of this study showed a significant increase in lipid peroxidation (LPO) resulting in high level of MDA in alloxan-induced diabetic rats kidneys with accompanying reduction in the levels of oxidative stress markers (SOD, CAT, GPx and GSH) in the kidney. This reduction in the levels of antioxidant enzymes in this study corroborates those of earlier reports (Kostolanska *et al.,* 2009). Reports have indicated that persistent hyperglycemia causes increased production of oxidative stress in alloxan-induced diabetes (Bonnefront *et al.,* 2000). Hence, excessive ROS produced leads to oxidative damage and increased LPO.

The antioxidant enzymes levels were found to be reduced in untreated alloxan-induced diabetic rats. In *in vivo* experimental models, tissue oxidative stress markers such as SOD, CAT and GSH are useful and reliable markers of antioxidant status while MDA is a sensitive and reliable marker for lipid peroxidation (Feillet-Coudray *et al.*, 1999; Kumar *et al.,* 2010). Hence, changes in the levels of these oxidative stress biomarkers reflect the antioxidant state of the body (El-Missiry and El-Gindy, 2000). In the present study, the administration of the leaf extract and fractions significantly counteracted the changes in oxidative stress biomarkers by inducing increases in the levels of antioxidant enzymes/oxidative stress markers.

Conclusion

The results of this study show that the leaf extract and fractions of *S. anomalum* possess kidney protective and antioxidantive stress potentials attributable to the activities of its phytochemical constituents.

Acknowledgements

The authors are grateful to Mr Nsikan Malachy of Pharmacology and Toxicology Department for providing technical assistance.

References

Baskar AA, Al Numair KS, Paulraj MG, Alsaif MA, Muamar M, Ignacimuthu S. (2012) .β-sitosterol prevents lipid peroxidation and improves antioxidant status and histoarchitecture in rats with 1,2-dimethylhydrazine-induced colon cancer. *Journal of Medicinal Food* 15(4):335-43.

Baynes JW, Thorpe SR. (1999).Role of oxidative stress in diabetic complications: a new perspective on an old paradigm. *Diabetes.* 48:1-9

Bonnefront RD, Bastard JP, Jaudon MC, Delattre J. (2000). Consequences of the diabetic status on the oxidant/ antioxidant balance. *Diabetes and Metabolism.* 26: 163-176.

Bukenya ZR, Hall JB. (1988). *Solanum* (Solanaceae) in Ghana. *Bothalia* 18(1): 79–88.

Burkill HM. (2000). The useful plants of West Tropical Africa. 2nd Edition. Volume 5, Families S–Z, Addenda. Royal Botanic Gardens, Kew, United Kingdom. 686 pp.

Dasgupta N, Muthukumar SP, Murthy PS. (2016). *Solanum nigrum*: Natural food against diabetes and its bioactive compounds. *Res J Med Plants* 10: 181-193.

Desai S, Tatke P, Gabhe SY (2015).Quantification of diosgenin in extracts and formulations containing *Solanum nigrum. International Journal of Pharmaceutical Sciences and Research.* 6(2): 676-681.

Dixit Y, Kar A. (2010). Protective role of three vegetable peels in alloxan induced diabetes mellitus in male mice. *Plant Foods Human Nutrition* 65:284-89.

Doss A, Palaniswamy M, Angayarkanni J, Dhanabalan J.(2009). Antidiabetic activity of water extract of *Solanum trilobatum* (Linn.) in alloxan-induced diabetes in rats. *African Journal of Biotechnology* 8 (20): 5562-5564.

Ellman GL. (1959). Tissue sulfhydryl groups. *Arch Biochem Biophys*. 82: 70-77.

El-Missiry MA, El-Gindy AM. (2000). Amelioration of alloxan induced diabetes mellitus and oxidative stress in rats by oil from *Eruca sativa* seeds. *Ann Nutr Metab.*, 44: 97-100.

Esterbauer H, Cheeseman KH. (1990). Determination of aldehydic lipid peroxidation products:malonaldehyde and 4-hydroxynonenal. *Methods Enzymol.* 186: 407–421.

Farah AO, Nooraain H, Noriham A, Azizah AH, Nurul HR.(2013). Acute and oral subacute toxicity study of ethanolic extract of *Cosmos caudatus* leaf in Sprague Dawley Rats. *Int J Biosci, Biochem Bioinformatics*. 3(4): 301-305.

Feillet-Coudray C, Rock E, Coudray C. (1999). Lipid peroxidation and antioxidant status in experimental diabetes. *Clinica Chimica Acta* 284: 31-43.

Gupta R, Sharma AK, Dobhal MP, Sharma MC, Gupta RS. (2011). Antidiabetic and antioxidant potential of β-sitosterol in streptozotocin-induced experimental hyperglycemia. *Journal of Diabetes.* 3(1):29-37.

Heble MS, Narayanaswami S, Chadha MS (1967). Diosgenin and beta-sitosterol: isolation from *Solanum xanthocarpum* tissue cultures. *Science* 13;161(3846):1145.

Ivorra MD, D'Ocon MP, Paya M Villar A. (1988). Antihyperglycemic and insulin-releasing effects of beta-sitosterol 3-beta-D-glucoside and its aglycone, beta-sitosterol, *Arch. Int. Pharmacodyn. Ther.*, 296, 224– 231.

Jain PG, Patil D J, Nayase PG, Surana S J, Patil PP.(2020). Protective effect of diosgenin on streptozotocin induced diabetic nephropathy in experimental rats. *International Journal of Pharmaceutical Sciences and Drug Research* 12(2): 201-207

Kanchan DM, Somani GS, Peshattiwar VV, Kaikini AA, Sathaye S (2016). Renoprotective effect of diosgenin in streptozotocin induced diabetic rats *Pharmacological Reports* 68:370–377.

Kostolanska J, Jakus V, Barak L. (2009). Glycation and lipid peroxidation in children and adolescents with type 1 diabetes mellitus with and without diabetic complications. *J Pediatr Endocrinol Metab.* 22:635-43.

Kumar PP, Kumaravel S, Lalitha C. (2010). Screening of antioxidant activity, total phenolics and GC-MS study of *Vitex negundo*. *Afr J Biochem Res* 4 (7): 191-195.

Lawrence RA, Burk RF. (1976). Glutathione peroxidase activity in selenium- deficient rat liver. *Biochem Biophys Res Comm* 71: 952-958.

Leng J, Li X, Tian H, Liu C, Guo Y, Zhang S, Chu Y, Li J, Wang Y , Zhang L.(2020). Neuroprotective effect of diosgenin in a mouse model of diabetic peripheral neuropathy involves the Nrf2/HO-1 pathway. *BMC Complementary Medicine and Therapies*(2020) 20:126

Lenzen, S. (2008). The mechanisms of alloxan- and streptozotocin-induced diabetes. *Diabetologia* 51(2): 216-226.

Loeb S. (1991). Clinical Laboratory Test: values and implication. Springhouse corporation, Springhouse, Pennsylvania. Pp.223 – 226.

Marklund S, Marklund G. (1974). Involvement of superoxide anion radical in the autooxidation of pyrogallol and a convenient assay for superoxide dismutase. *Eur J Biochem,* 47: 469 - 474.

Mathews CE, Leiter EH. (1999). Constitutive differences in antioxidant defense status distinguish alloxan-resistant and alloxan-susceptible mice. *Free Radic Biol Med* 27: 449-455.

Mirunalini S, Arulmozhi V, Krishnaveni M. (2012). Protective effect of *Solanum nigrum* fruit extract on functional status of liver and kidney against ethanol induced toxicity. *Journal of Biochemistry and Biotechnology*. 3(4):339-43.

Nduka N. (1997). Clinical Biochemistry for students of Chemical Pathology.1st edn, Longman, Lagos, Nigeria.Pp. 79.

Nyaga SN, Mathiu PM, Onyango CM, Areba GO.(2019). Antidiabetic properties of *Solanum villosum* and *Solanum nigrum var sarrachoides* in a streptozotocin-induced diabetic mice model. *International Journal of Basic & Clinical Pharmacology*. 8(11): 2396-2402.

Offor SJ, Ubengama EE. (2015). Phytochemical and antidiabetic studies of ethanolic extracts and fractions of the fruits of *Solanum anomalum* Thonn. Ex. Schumach. *International Journal of Scientific Research and Education.*3 (9):4343-4350.

Okokon JE, Davis K, Umoh EE, Amazu LU (2017b). Antiinflammatory activity of leaf extract of *Solanum anomalum*. *Journal of Herbal Drugs.* 7(4):243-249.

Okokon JE, Nyong EE, Obot J, Davies K. (2019b). Anticonvulsant and depressant activities of ethanol leaf extract of *Solanum anomalum. Nigerian Journal of Pharmaceutical and Applied Sciences Research*. 8 (1): 73-79.

Okokon JE, NyongEE, Thomas PS, Udoh AE. (2019a). Antioxidant and antiulcer activities of ethanol leaf extract and fractions of *Solanum anomalum*. *Discovery Phytomedicine.* 6(2):20-25.

Okokon JE, Okokon PJ, Sahal D. (2017a). In vitro antiplasmodial activity of some medicinal plants from Nigeria. *International Journal of Herbal Medicine*. 5(5): 102 – 109.

Okokon JE, Opara KN, Azare B. (2016). Antimalarial activity of *Solanum anomalum* (Solanaceae). *Nigerian Journal of Pharmaceutical and Applied Sciences Research*. 5(1):1-6.

Okokon JE, Udoh AE, Nyong EE, Amazu LU. (2020). Analgesic activity ethanol leaf extract of *Solanum anomalum.African Journal of Pharmacology and Therapeutics.* 9(1):22-26.

Okokon JE, Etuk IC, Thomas P, Drijfhout FP, Claridge TM, Li W-W. (2022). In vivo antihyperglycaemic and antihyperlipidemic activities and chemical constituents of leaf extract and fractions of *Solanum anomalum* in alloxan-induced diabetic rats. *Biomedicine and Pharmacotherapy.* doi.org/10.1016/j.biopha.2022.113153

Okutana H, Ozcelik N, Yilmaz HR, Uz E. (2005). Effects of caffeic acid phenethyl ester on lipid peroxidation and antioxidant enzymes in diabetic rat heart. *Clin Biochem.,* 38: 191-196.

Paradies G, Petrosillo G, Paradies V, Ruggiero FM. (2011).Mitochondrial dysfunction in brain aging: role of oxidative stress and cardiolipin. *Neurochem Int.*, 58: 447-457.

Pari L, Saravanan G.(2002). Antidiabetic effect of cgent db, a herbal drug in alloxan-induced diabetes mellitus. *Biochemical Physical and Toxicol Pharmacol.* 131:19.

Pari L, Monisha P, Jalaludeen AM. (2012). Beneficial role of diosgenin on oxidative stress in aorta of streptozotocin induced diabetic rats. *Eur J Pharmacol*691: 143– 150.

Ping KY, Darah I, Chen Y, Sreeramanan S, Sasidharan S. (2013). Acute and subchronic toxicity study of *Euphorbia hirta* L. methanol extract in rats. *Biomed Res Intern.*1-14.

Ramsey I. (1986). *A synopsis of Endocrinology and metabolism*. 3rd edn. Wright, Bristol.pp. 215 -218.

Ramu, R., Shirahatti, P. S., Nayakavadi, S., Vadivelan, R., Zameer, F., Dhananjay, B. L., Nagendra Prasad, M. N. 2016. The effect of a plant extract enriched in stigmasterol and β-sitosterol on glycaemic status and glucose metabolism in alloxan-induced diabetic rats. *Food and Function.* 7(9): 3999-4011.

Rhetso T, Shubharani R, Roopa MS, Sivaram V. (2020). Chemical constituents, antioxidant, and antimicrobial activity of *Allium chinense* G. Don. *Future Journal of Pharmaceutical Sciences* 6:102. doi.org/10.1186/s43094-020-00100-7.

Robinson G, Johnson, D. E. (1997). Metabolic disorder:

Diabetes.In:*Mechanism of disease. An introduction to Clinical Science.* 1st edn, Cambridge University press, Cambridge.

Roghani-Dehkordi F, Roghani M, Baluchnejadmojarad T. (2015). Diosgenin mitigates streptozotocin diabetes-induced vascular dysfunction of the rat aorta: the involved mechanisms. *J Cardiovasc Pharmacol.* 66(6):584–92.

Saravanan G, Ponmurugan P, Deepa MA, Senthilkumar B. (2014). Modulatory effects of diosgenin on attenuating the key enzymes activities of carbohydrate metabolism and glycogen content in streptozotocin-induced diabetic rats, *Can J Diabetes* 38(6): 409-14.

Selvi. R1, Yogananth, N (2016). In vitro evaluation of antidiabetic potential of leaf and stem extracts of *Solanum xanthocarpum* and *Solanum nigrum. Int. J. Adv. Res. Biol. Sci.* 3(12): 191-195.

Sengottaiyan A, Praburaman L, Manoharan K, Rajinikanth R, Govarthanan M, Selvankuma (2012). Hypoglycemic and hypolipidemic activity of *Solanum nigrum* in alloxan induced diabetic albino rats *International Journal of Pharmaceutical Sciences and Research.* 3(8): 2841-2848

Sengupta S, Nandi I, Bhattacharyya DK, Ghosh M (2018). Anti-oxidant and anti-bacterial properties of 1-Octacosanol isolated from rice Bran Wax. *J Plant Biochem Physiol* 6: 206. doi: 10.4172/2329-9029.1000206

Sheela CG, Augusti KT. (1992). Antidiabetic effects of S-Allyl cysteine sulphoxide isolated from Garlic *Allium sativum* Linn. *Ind J Exper Biol.* 30: 523-526.

Shirwaikar A, Rajendran K, Punitha ISR (2005). Antidiabetic activity of alcoholic stem extract of *Coscinium fenestratum* in streptozotocin nicotinamide induced type 2 diabetic rats. *J Ethnopharmacol.* 93:369-374.

Singh SK, Kesari AN, Gupta RK, Jaiswal D, Watal G.(2007). Assessment of antidiabetic potential of *Cynodon dactylon* extract in streptozotocin diabetic rats. *Journal of Ethnopharmacology*. 114(2):174-179.

Udobang J, Okokon JE, Ukpong BD, Akpan SJ. (2022). Analysis of ethanol extract of *Solanum anomalum* leaves for antidiarhoeal activity. *Journal of Current Biomedical Research.*2(2):145-157.

Umamageswari, M.S.; Karthikeyan, T.M.; Maniyar, Y.A. (2017). Antidiabetic activity of aqueous extract of *Solanum nigrum* Linn berries in alloxan induced diabetic wistar albino rats. *J. Clin. Diagn. Res.* 11:FC16–FC19.

WHO expert committee on diabetes mellitus. Tech. Rep. Series No.646.World Health Organisation, Geneva, 1980.

Widyawati T, Syarifah S, Ichwan M, Anggraini DR, Wahyuni AS. (2018). Antihyperglycemic and pancreatic protective effect of squalene in streptozotocin-induced diabetic rat. In: Proceedings of the 3rd International conference of Computer, Environment, Agriculture, Social Science, Health Science, Engineering and Technology (ICEST 2018), pages 483-486.