Hippocratea africana root extract and fractions attenuate paracetamol-induced oxidative stress and kidney injuries in rats

Kufre Noah[1], Utibe A. Edem[1], Jude E. Okokon[1], Nwakaego O. Ebong[2*]

[1]Department of Pharmacology and Toxicology, Faculty of Pharmacy, University of Uyo, Uyo, Nigeria.
[2]Department of Pharmacology and Toxicology, Faculty of Pharmacy, Madonna University, Rivers state, Nigeria.

Submitted: 5th July., 2023; Accepted: 11th July., 2023; Published online: 31st Aug., 2023
DOI: https://doi.org/10.54117/jcbr.v3i4.2
**Corresponding Author: Nwakaego O. Ebong; nwakaebong@gmail.com; +234-8132321014*

Abstract

Hippocratea africana root used locally in the treatment of poisoning was investigated to confirm its antidotal potential in rats. The root extract (200-600 mg/kg) and fractions; dichloromethane (DCM) and aqueous, 400 mg/kg) were evaluated for nephroprotective activity against paracetamol-induced kidney injury in rats. Anti-oxidative stress and renoprotective potentials of root extract and fractions were assessed by determining oxidative stress markers levels, kidney function parameters and histopathology in rats. The root extract and fractions caused significant ($p<0.05 – 0.001$) increases in the levels of oxidative stress markers (SOD, CAT, GPx, GSH) in the kidney, while MDA level was decreased. The root extract/fractions caused significant ($p<0.05$-0.001) reduction of elevated serum levels of creatinine and urea of the rats, while the electrolytes levels were considerably reduced though not significant. Histology of kidney revealed absence or significant reductions in pathological features in the treated rats compared to paracetamol treated group group. The results show that the root extract and fractions of *H.africana* have antioxidative stress and nephroprotective potentials which may be due to the antioxidant activities of their phytochemical constituents.

Keywords: *Hippocratea africana*, anti-toxicant, oxidative stress, kidney protective, antioxidant

Introduction

Hippocratea africana (Willd.) Loes. ex Engl. (Celastraceae) syn. *Loeseneriella africana* (Willd.) N.Hallé is a perennial climber found in tropical Africa (Hutchison and Dalziel, 1973) and commonly called ‘Eba

enang enang' by the Ibibios of Nigeria. The Ibibios of Southern Nigeria use the plant root traditionally as febrifuge, anticonvulsant, malaria remedy, analgesic, antidiabetic and antidiarrheal (Okokon *et al.,* 2006). The root is also utilised for its antidotal potential to treat liver and kidney diseases (Etukudo, 2000; 2003; Ajibesin *et al*., 2008). Reports of antimalarial (Okokon *et al.*, 2006; 2021), antioedema and antinociceptive (Okokon *et al.,* 2008), antidiabetic and hypolipidemic (Okokon *et al.*, 2010; 2022), antidiarrhoeal and antiulcer (Okokon *et al.,* 2011), hepatoprotective (Okokon *et al.*, 2013a), antileishmanial, cytotoxicity and cellular antioxidant (Okokon *et al.,* 2013b), antibacterial, anticonvulsant and depressant (Okokon *et al.,* 2014), in vivo alpha amylase and alpha glucosidase inhibitory (Okokon *et al.,* 2021), *in vitro* antioxidant (Umoh *et al.,* 2021;Okokon *et al.,* 2022) activities of the root extract have been published. Moreso, the presence of spirohexane-1-carboxylic acid, ethyl ester, 3-methoxy-2-methylphenol,2,3-benzofurandione,6-hydroxy-4-(p-hydroxybenzyl), $^{\delta}$-3-Carene and α-terpineol in ethyl acetate fraction (Okokon *et al.,* 2017) and the presence of monoterpenes (thujene, limonene, linalool, α-phellandrene, α-terpineol and sabinene) and sesquiterpenes (dehydromevalonic lactone), in the n-hexane fraction of the root extract (Okokon *et al*., 2013a) have been documented. Umoh *et al*.(2021) isolated two xanthones; 1,3,6,7-tetrahydroxyxanthone and 1,3,6-trihydroxy-7-methoxyxanthone, from the root of *H. africana.* We report renoprotective and antioxidative stress effects of the root extract and fractions of *H. africana* against paracetamol-induced kidney injury in rats.

Materials and Methods

Plants collection

Fresh roots of *Hippocratea africana* were collected in a farmland in Uruan area, Akwa Ibom State, Nigeria in November, 2021. Identification and authentication of the plant was carried out by a taxonomist, Prof Margaret Bassey, in the Department of Botany and Ecological Studies, University of Uyo, Uyo, Nigeria. Hebarium specimen (UUPHB 30(i) was deposited at Department of Pharmacognosy and Natural Medicine Herbarium, University of Uyo.

Preparation of extract and fractions

Fresh roots of *H. africana* were washed, cut into smaller pieces and dried under shade for two weeks. They were powdered using electric grinder. The pulverised root of *H. africana* (HAE) was soaked in ethanol (50%) for 72 h. The liquid filtrate obtained was

concentrated in a rotary evaporator at 40˚C. The crude extract (20 g) was dissolved in 500 mL of distilled water and partitioned with equal volume of dichloromethane (DCM, 5 x 500 mL) till no colour change was observed, to obtain DCM and aqueous fractions. The extract and fractions were stored at 4˚C in a refrigerator until used for the experiment.

Animals

Male albino Wistar rats used in this study were sourced from University of Uyo Animal house and sheltered in plastic cages. The rats were fed with pelleted standard Feed (Guinea feed) and given unlimited access to water. Approval for the study was gotten from Faculty of Pharmacy Animal Ethics Committee, University of Uyo (UU/FP/AE/22/055).

Effect of Ethanol Root Extract and fractions of Hippocratea africana on Paracetamol-induced kidney injury in Rats

In this model, forty (40) rats were randomly divided into eight (8) groups of 5 rats each and treated as follows; Group 1 served as the normal control group and animals in this group were administered 10 mL/kg of distilled water orally for eight consecutive days. Groups 2 rats which served as the organotoxic group, were administered with 10 mL/kg of normal saline orally for 8 days. Groups 3 -5 - served as the extract treated groups and were respectively and orally administered with 200, 400 and 600 mg/kg of root extract daily for 8 days. Groups 6 and 7 animals were pre-treated with 400 mg/kg of DCM and aqueous fractions respectively for 8 days. Group 8 which served as the positive control group were orally treated with 100 mg/kg of silymarin for 8 days.

On the eighth (8th) day, animals in groups 2 - 8 received paracetamol (2.0 g/kg, orally).

Collection of Blood Samples and Organs

After 8 days of treatment (24 hours after the last treatment) the rats were weighed again and sacrificed under light diethyl ether vapour. Blood samples were collected by cardiac puncture into plain bottles and used immediately. The blood samples were centrifuged immediately at 2500 rpm for 15 minutes to separate the serum at room temperature to avoid haemolysis and used for biochemical assays. The kidneys were surgically removed, weighed and one kidney fixed in 10% formaldehyde for histological process.

Biochemical Analysis

Kidney function test

The following biochemical parameters were determined as markers of kidney function using diagnostic kits at the Chemical Pathology Department of University of Uyo Teaching Hospital; levels of electrolytes (Na, K, Cl, and HCO_3), creatinine, uric acid and urea.

Preparation of renal homogenate

The other kidney removed was dissected free from the surrounding fat and connective tissue. Each kidney was longitudinally sectioned, and renal cortex was separated and kept at −8°C. Subsequently, renal cortex was homogenized in cold potassium phosphate buffer (0.05 M, pH 7.4). The renal cortical homogenates were centrifuged at 5000rpm for 10 min at 4◦C. The resulting supernatant was used for the determination of malondialdehyde (MDA) content (Esterbauer and Cheeseman, 1974), superoxide dismutase (SOD) (Marklund and Marklund, 1974), catalase (CAT) (Sinha, 1972), glutathione peroxidase (GPx) (Lawrence and Burk, 1976), and reduced glutathione (GSH) (Ellman, 1959) activities using colorimetric assay**.** These oxidative stress markers were used to assess antioxidative stress potentials of the extract.

Histopathological studies

The excised kidneys fixed in 10 % buffered formalin were used for histological processes. They were processed and stained with haematoxylin and eosin (H&E) (Drury and Wallington, 1980), according to standard procedures at Department of Chemical Pathology, University of Uyo Teaching Hospital, Uyo. Morphological changes observed and recorded. Histologic pictures were taken as micrographs.

Statistical Analysis

Data obtained from this work were analysed statistically using ANOVA (one –way) followed by a post test (Tukey-Kramer multiple comparison test). Differences between means were considered significant at 5% level of significance ie $p \leq 0.05$.

Results

Effect of *H. africana* root extract on organs weights of rats with PCM-induced toxicity

The administration of paracetamol as well as the extract/fractions treatment did not cause any significant ($p>0.05$) effect on the kidney weights of the rats (Table 1).

Table 1: Effect of *H. africana* root extract on organs weights of rats with paracetamol induced toxicity

Parameters/Treatment	**Dose mg/kg**	**Kidney**
Normal control	-	1.30±0.08
Paracetamol	2000	1.27±0.10
Silymarin+PCM	100	1.08±0.06
Extract+PCM	200	1.17±0.06
	400	1.16±0.10
	600	0.98±0.28
Aqueous fraction	400	1.40±0.10
DCM fraction	400	1.31±0.04

Data were expressed as mean ±SEM. Not significant at $p>0.05$ when compared to normal and organotoxic control. n = 5.

Evaluation of effect of root extract and fractions of *H. africana* on kidney function parameters of paracetamol-induced kidney injury in rats.

Administration of rats with paracetamol (2 g/kg) caused significant ($p<0.05$-0.001) elevation of serum urea, creatinine and electrolytes (K^+, Na^+, Cl^- and HCO^-_3) when compared to normal control. These increased levels of serum urea, creatinine and electrolytes were significantly ($p<0.05$ - 0.001) reduced following pre-treatment of the rats with silymarin and root extract/fractions (200 – 600 mg/kg), though non dose-dependently, with the aqueous fraction having the greatest effect. Also, the decrease in the level of Cl- was only significant ($p<0.05$) in the groups treated with root extract (400mg/kg) and silymarin respectively when compared to the paracetamol onky treated group (Table 2).

Effect of *H. africana* root extract and fractions on kidney oxidative stress markers of rats with paracetamol-induced toxicity

Table 3 shows the effect of root extract and fractions of *H. africana* on kidney oxidative stress markers in rats with paracetamol-induced organs injuries. Administration of paracetamol was found to significantly ($p<0.01$-0.001) reduce the levels of GSH, GPx, CAT, GST and SOD, while MDA level was highly increased. Pretreatment of rats with PCM-induced organs injuries with root extract and fractions *of H. africana* and silymarin caused significant ($p<0.05$-0.001) and non dose- dependent elevation in the levels of GSH, GPx, CAT, GST and SOD when compared to the paracetamol only treated group. However, pre-treatment of rats with root extract and fractions of *H. africana* caused significant ($p<0.05$-0.001) reductions in the levels of MDA of various treatment groups (Table

Table 2: Effect of *H. africana* root extract and fractions on kidney function parameters of rats with paracetamol-induced toxicity

Treatment	Dose mg/kg	Urea (mMol/L)	Creatinine (µmol/L)	Chloride (mMol/L)	Potassium (mMol/L)	Sodium (mMol/L)	Bicarbonate (mMol/L)
Control	10	5.20± 0.43	105.75±7.88	40.50±3.61	3.77± 0.12	108.25± 2.68	21.10± 0.12
Paracetamol	2000	7.55± 0.41^{c}	150.25±7.92^{b}	55.0±2.55^{a}	6.30± 0.23^{c}	176.0± 3.18^{c}	32.41± 0.24^{a}
Crude extract	200	7.27±0.20^{a}	146.25± 3.83^{b}	43.25±1.65	5.30± 0.29^{e}	157.75±7.02^{b,e}	24.02± 0.33^{d}
	400	6.42±0.14^{a}	129.25±2.95^{e}	40.50±4.66^{d}	5.25± 0.35^{e}	160.25±8.05^{b,e}	22.36± 0.20^{d}
	600	5.07±0.14^{f}	103.25± 2.49^{e}	48.66±1.20	3.35± 0.29^{f}	103.50±1.19^{f}	21.65± 1.14^{d}
Aqueous Fraction	400	5.95±0.10^{d}	121.25±1.75^{d}	50.50±1.84	3.55± 0.21^{f}	108.75±2.68^{f}	23.29± 1.15^{d}
DCM fraction	400	6.22±0.42	126.75±8.34^{d}	46.5±3.14	3.27± 0.08^{f}	104.25±1.10^{f}	22.18± 2.18^{d}
Silymarin	100	4.37±0.31^{f}	77.75±9.91^{f}	39.0±1.68^{d}	3.05± 0.10^{f}	104.25±1.10^{f}	20.32± 1.60^{d}

Data is expressed as MEAN ± SEM, Significant at [a]p<0.05, [b]p<0.01, [c]p<0.001, when compared to control; Significant at [d]p<0.05, [e]p<0.01, [f]p<0.001 compared to organotoxic group.. (n=5)

Table 3: Effect of *H. africana* root extract and fractions on kidney oxidative markers of rats with paracetamol-induced toxicity

Treatment	Dose (mg/kg)	SOD (U/ml)	CAT (U/g of protein)	GPx (µg/ml)	GSH (µg/ml)	GST	MDA (µMol/ml)
Control	10	0.63±0.04	0.10±0.01	0.086±0.003	0.43±0.13	0.50±0.02	0.54±0.14
Paracetamol	2000	0.41±0.03[b]	0.05±0.00[a]	0.033±0.009[c]	0.22±0.04[a]	0.30±0.02[b]	0.88±0.02[a]
Crude extract	200	0.58±0.02[d]	0.11± 0.02[f]	0.074±0.002[c,d]	0.46± 0.12[e]	0.38±0.01[a]	0.50± 0.02[d]
	400	0.59±0.01[d]	0.14±0.03[b]	0.084±0.003[c,d]	0.48± 0.31[e]	0.43±0.05[d]	0.43±0.01[e]
	600	0.62±0.02[e]	0.13± 0.05[f]	0.068±0.001[e]	0.42± 0.14[d]	0.51±0.01[e]	0.46±0.01[e]
Aqueous Fraction	400	0.58±0.01[d]	0.14±0.02[f]	0.078±0.001[f,d]	0.52± 0.21[f]	0.44±0.03[d]	0.51± 0.05[d]
DCM fraction	400	0.68±0.02[d]	0.16±0.05[f]	0.091±0.001[a,f]	0.48± 0.02[f]	0.55±0.01[f]	0.45± 0.03[e]
Silymarin	100	0.72±0.01[e]	0.12±0.01	0.076±0.008[f]	0.53±0.15[f]	0.49±0.01[d]	0.44±0.08[e]

Data is expressed as MEAN ± SEM, Significant at [a]p<0.05, [b]p<0.01, [c]p<0.001, when compared to control; Significant at [d]p<0.05, [e]p<0.01, [f]p<0.001 compared to organotoxic group.. (n=5).

Effect of *H. africana* root extract and fractions on lipid profile of rats with paracetamol-induced toxicity

The administration of paracetamol (2g/kg), root extract and fractions of *H. africana* to rats did not cause any significant effect ($p>0.05$) on the level of total cholesterol, triglyceride, high density lipoprotein, low density lipoprotein and very low density lipoprotein of rats with paracetamol–induced injuries. Similarly, silymarin was observed to have no effect on the lipid profile of the animals (Table 4)

Table 4: Effect of *H. africana* root extract and fractions on lipid profile of rats with paracetamol-induced toxicity

Treatment	Dose mg/kg	Total cholesterol (mMol/L)	Triglyceride (mMol/L)	HDL-C (mMol/L)	LDL-C (mMol/L)	VLDL (mMol/L)
Control	10	2.30± 0.28	1.04±0.07	1.39±0.04	1.37± 0.18	0.47± 0.03
Paracetamol	2000	3.10± 0.15	1.01±0.06	1.19±0.08	2.38± 0.11	0.46± 0.02
Crude extract	200	3.05±0.28	1.13± 0.06	1.40±0.06	1.83± 0.49	0.51±0.02
	400	2.45±0.15	0.92±0.05	1.23±0.02	1.73± 0.15	0.42±0.02
	600	2.92±0.18	1.13±0.03	1.38±0.06	2.09± 0.21	0.51±0.01
Aqueous Fraction	400	2.55±0.06	0.98±0.03	1.19±0.07	1.79± 0.05	0.45± 0.01
DCM fraction	400	2.65±0.09	0.92±0.03	1.25±0.03	1.76± 0.06	0.42± 0.01
Silymarin	100	2.60±0.09	0.90±0.02	1.34±0.04	1.66± 0.11	0.41± 0.01

Data is expressed as MEAN ± SEM, Significant at $^{a}p<0.05$, $^{b}p<0.01$, $^{c}p<0.001$, when compared to control; Significant at $^{d}p<0.05$, $^{e}p<0.01$, $^{f}p<0.001$ compared to organotoxic group.. (n=5)

Effect of root extract and fractions of *H. africana* on histology of rat kidney in paracetamol-induced nephrotoxicity

Histological sections of kidney of rats receiving various treatments at magnification (x400) stained with H&E method revealed that Group 1 (normal control, A) treated distilled water (10 mL/kg) had kidney section that showed normal renal tubules and glomeruli, no evidence of pathology was seen (Figure 1). The organotoxic group (Group 2, B) treated with paracetamol (PCM), 2000 mg/kg showed abnormal glomeruli and renal tubule. There were atrophic glomeruli (Figure 1). Group 3 (C) rats treated with 200 mg/kg of *H. africana* root extract and PCM showed normal renal tubules and glomerulus and focal area of interstitial haemorrhage. Rats in group 4 (D) treated with 400 mg/kg of *H. africana* root extract and PCM showed distorted parenchymal with both normal and dilated renal tubules with flattened epithelium. Diffused interstitial inflammatory infiltrates and focal necrotic area were also present. Group 5 (E) rat treated with 600 mg/kg of *H. africana* root extract and PCM had kidney section that showed normal renal tubules, glomeruli and a focal remarkable congestion of glomerular capillaries. Kidney section of rats in group 6 (F) treated with aqueous fraction of *H. africana* root showed normal renal tubules and glomeruli with no evidence of pathology seen. Group 7 (G) rats treated with dichloromethane fraction of *H. africana* root and PCM had kidney section which showed normal renal tubules and glomeruli with no evidence of pathology seen. The rats treated with silymarin (100 mg/kg) and PCM in group 8 (H) had kidney section that revealed normal renal tubules and glomeruli without any evidence of pathology seen (Figure 1).

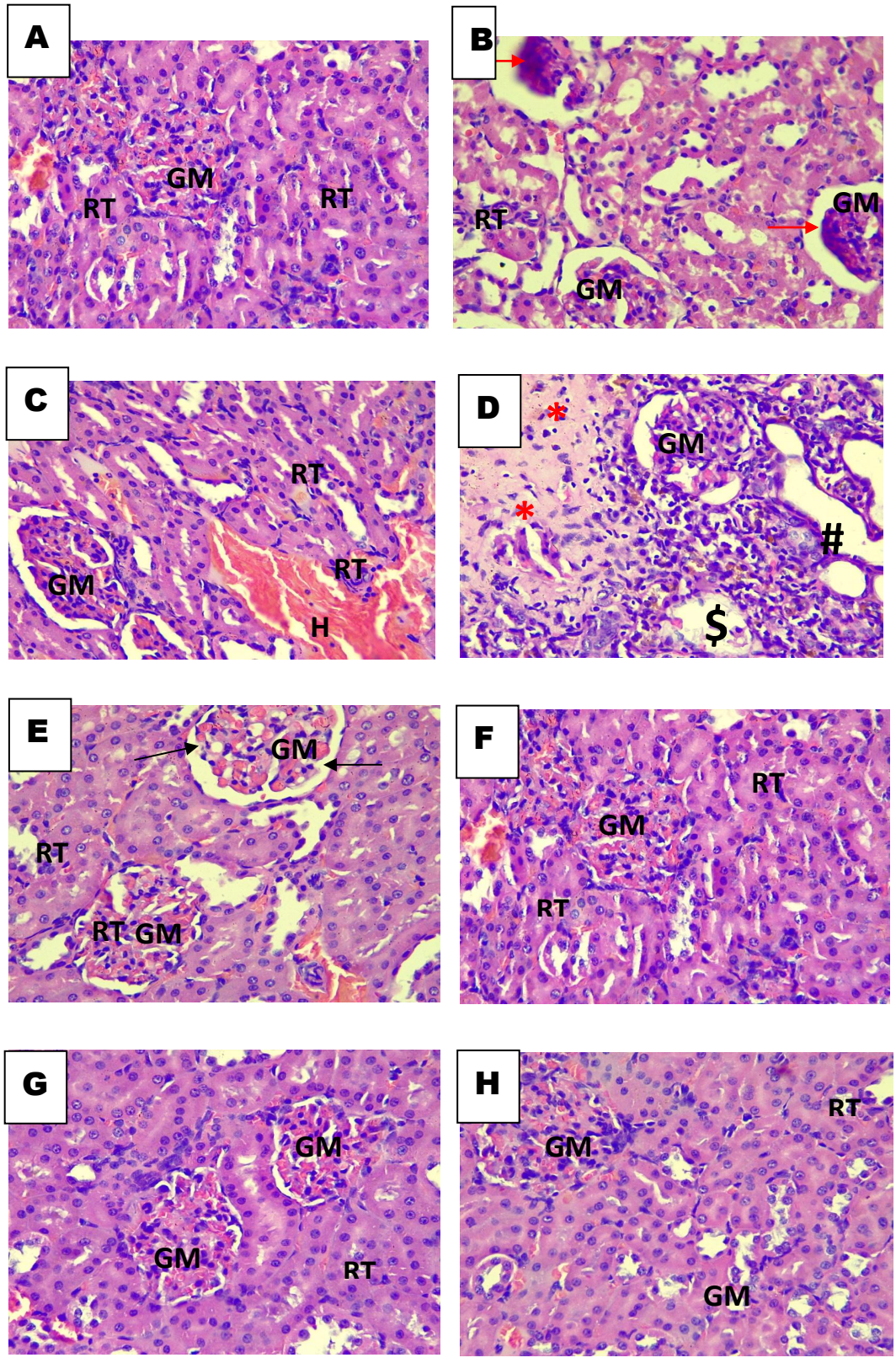

Figure 1: Kidney histological sections of rats treated with distilled water 10 mL/kg(A), Paracetamol 2g/kg (B), *H. africana* extract 200 mg/kg (C), 400 mg/kg, (D), 600 mg/kg (E), Aqueous fraction (F), DCM fraction (G), Silymarin 100 mg/kg (H)showing normal renal tubules (RT) and glomeruli (GM), focal area of interstitial haemorrhage (H),diffused

interstitial inflammatory infiltrates (**red arrowhead**), focal necrotic area (**red asterisks**) and interstitial scaring (**$**),dilated renal tubules (#) and remarkable congestion of glomerular capillaries (thin arrow). H&E Stain, x 400 magnification

Discussion

The pre-treatment of the rats with the root extract and fractions of *H. africana* ($p<0.01$) significantly lowered the serum levels of urea, creatinine and electrolytes dose dependently resulting from paracetamol induced renal injuries when compared to the paracetamol group, thus, demonstrating the nephroprotective activity of the root extract and fractions. These results corroborate earlier report by Isik *et al.,* (2006) who reported serum urea and creatinine levels elevations in rats resulting from paracetamol (1 g/kg) administration. These elevations in the levels of urea and creatinine which portrays nephrotoxicity (Laskshmi and Sudhakar, 2010) was linked to oxidative stress. At high doses, paracetamol exerts toxic effect which leads to tissue damage due to its bioactivation to a toxic electrophile, *N*-acetyl *p*-benzoquinone imine (NAPQI), which interact with tissue macromolecules, and probably oxidizes lipids, or the critical sulphydryl groups (protein thiols) as well as alters the homeostasis of calcium (Lin *et al.,* 1997). The kidney is exposed to toxic effect of p-amino phenol, formed from paracetamol by deacetylation and excreted in urine. This plays a major role in the pathogenesis of paracetamol-induced renal damage (Mugford and Tarlolf, 1997). Hepatically derived glutathione conjugates (Trumper *et al.,* 1996) and nitric oxide (Li *et al.,* 2003) are also associated in the pathogenesis of paracetamol-induced renal injury. Histopathological examination of the kidneys of the paracetamol only group confirmed the induction of kidney injuries, evidenced by severely atrophied glomeruli and abnormal renal tubule. The elevation of GSH, GPx, SOD and CAT and reduction in MDA level in the kidney tissues of extract/fractions-treated rats further confirmed the involvement of oxidative stress in paracetamol-induced nephrotoxicity. This suggests that the mechanism of nephroprotective activities of the root extract and fractions involves the antioxidant activity of the extract/fraction. The observed antioxidant activity was mainly due to the presence of phytochemical compounds in the extract which have

been reported to posses anti-oxidant properties (Umoh *et al.,* 2021).

Furthermore, the nephroprotective properties of the extract/fractions evidenced by the reduction in the levels of kidney function (creatinine, urea, Na, K, Cl and bicarbonate) markers is consistent with the histological findings which demonstrated a fairly intact renal tissues in the extract/fractions-treated groups, relative to the PCM-only group, implying that the root extract and fractions protected the renal tissues from paracetamol-induced injuries.

Antioxidant enzymes are involved in the scavenging of the free radicals to form hydrogen peroxide and safer molecules, hence reducing the toxic effect caused by these radicals. SOD and CAT are important enzymes in the enzymatic antioxidant defense system (Curtis *et al.,* 1972). The root extract has been reported to increase hepatic antioxidant enzymes such as SOD and CAT (Okokon *et al.*, 2013a). This implies that the root extract may also be acting through the reduction of reactive free radicals due to the presence of antioxidant chemicals, which reduces oxidative damage to the tissues. This effect could be due to the free radicals scavenging potentials of the root extract/fractions (Okokon *et al.,* 2013a; 2021), which can be attributed to the activities of its phytochemical constituents such as monoterpenes, sesquiterpenes and xanthones earlier reported to be present in this root extract (Okokon *et al.,* 2013a; 2021; Umoh *et al.,* 2021).

Conclusion

The results of this study shows that the root extract and fractions of *H. africana* possess nephroprotective properties exerted through the antioxidative stress activities of its phytochemical constituents.

References

Ajibesin KK, Ekpo BA, Bala DN, Essien EE and Adesanya SA. (2008)_. Ethnobotanical survey of Akwa Ibom State of Nigeria. J Ethnopharmacol., 115(3): 387-408. doi:10.1016/j.jep.2007.10.021

Curtis SJ, Moritz M, Snodgrass PJ. (1972). Serum enzymes derived from liver cell fractions. I. The response to carbon tetrachloride intoxication in rats. Gastroenterology., 62(1): 84-92.

Drury RA and Wallington EA. (1980). Carleton's Histological Techniques, fifth ed. Oxford University Press, New York, pp. 195.

Ellman GL. (1959). Tissue sulfhydryl groups. Arch Biochem Biophys., 82(1): 70-77. doi:10.1016/0003-9861(59)90090-6

Esterbauer H and Cheeseman KH. (1990). Determination of aldehydic lipid peroxidation products: malonaldehyde and 4-hydroxynonenal. *Methods Enzymol*., 186: 407-421. doi:10.1016/0076-6879(90)86134-h

Etukudo I. (2000). Forests: Our Divine Treasure. Dorand Publishers, Nigeria, pp. 156-180.

Etukudo I. (2003). Ethnobotany: Conventional and Traditional Uses of Plants. The Verdict Press, Nigeria, pp. 83 – 134.

Hutchinson J and Dalziel JM. (1973). Flora of West Tropical Africa, second ed. Crown Agents for Overseas Government and Administration, 1(2), pp. 638.

Isik B, Bayrak R, Akcay A and Sogut S. (2006). Erdosteine against acetaminophen induced renal toxicity. Mol Cell Biochem., 287(1-2): 185-191.

Lakshmi BVS and Sudhakar M. 2010. Protective Effect of *Zingiber officinale* on Gentamicin-Induced Nephrotoxicity in Rats. Int J Pharmacol., 6(1): 58-62

Lawrence RA and Burk RF. 1976. Glutathione peroxidase activity in selenium-deficient rat liver. Biochem Biophys Res Commun., 71(4): 952-958. doi:10.1016/0006-291x(76)90747-6

Li C, Lui J, Saaedra JE, Keefer LK and Waalkes MP. (2003). The Nitric oxidedonor, V-PYRRO/NO, protects against acetaminophen-inducednephrotoxicity in mice. Toxicol., 189:173–80.

Lin GD, Chattopadhyay D, Maki M, Wang KK, Carson M, Jin L, Yuen PW, Takano E, Hatanaka M, DeLucas LJ and Narayana SV. (1997). Crystal structure of calcium bound domain VI of calpain at 1.9 A resolution and its role in enzyme assembly, regulation, and inhibitor binding. Nat Struct Biol., 4(7): 539-547. doi:10.1038/nsb0797-539

Marklund S and Marklund G. (1974). Involvement of the superoxide anion radical in the autoxidation of pyrogallol and a convenient assay for superoxide dismutase. Eur J Biochem., 47(3): 469-474.

Mugford CA and Tarloff JB. (1997). The contribution of oxidation and deacetylation to acetaminophen nephrotoxicity in female Sprague-Dawley rats. Toxicol Lett., 93(1): 15-22.

Okokon JE, Ita BN and Udokpoh AE. (2006). The in-vivo antimalarial activities of Uvaria chamae and Hippocratea africana. Ann Trop Med Parasitol., 100(7): 585-590.

Okokon JE, Akpan HD, Umoh EE and Ekaidem IS. (2011). Antidiarrhoeal and antiulcer activities of *Hippocratea africana* root extract. Pak J Pharm Sci., 24(2): 201-205.

Okokon JE, Antia BS, Umoh EE and Etim EI. (2010). Antidiabetic and hypolipidaemic activities of *Hippocratea africana*. Int J Drug Dev Res., 2: 501 -506.

Okokon JE, Antia BS and Umoh EE. (2008). Analgesic and antinflammatory effects of ethanolic root extract of *Hippocratea africana.* Int J Pharmacol., l4(1): 51-55.

Okokon JE, Chinyere CP, Bassey AL and Udobang JA. (2021). *In vivo* alpha amylase and alpha glucosidase activities of ethanol root extract and fractions of *Hippocratea africana*. South Asian J Parasitol., 5(4): 42-48.

Okokon JE, Chinyere PC, Amaechi P, Bassey AL and Thomas PS. (2022). Antioxidant, antidiabetic and hypolipidemic activities of ethanol root extract and fractions of *Hippocratea africana*. Trop J Nat Prod Res., 6(3): 446-453.

Okokon JE, Dar A and Choudhary MI. (2013b). Immunomodulatory, cytotoxic and antileishmanial activities of *Hippocratea africana.* J Nat Pharmaceut., 4(2): 81 – 85.

Okokon JE, Davies K, Okokon PJ and Antia BS. (2014). Depressant, anticonvulsant and antibacterial activities of *Hippocratea africana*. Int J Phytother., 4 (3): 144 – 153.

Okokon JE, Nwafor PA, Charles U, Dar A and Choudhary MI. (2013a). The antioxidative burst and hepatoprotective effects of ethanolic root extract of *Hippocratea africana*

against paracetamol-induced liver injury. Pharm Biol., 51(7): 872 - 880.

Okokon JE, Okokon PJ and Sahal D. (2017). *In vitro* antiplasmodial activity of some medicinal plants from Nigeria. Int J Herbal Med., 5(5): 102-109.

Sinha, A. K. (1972). Colorimetric assay of catalase. *Analytical Biochemistry,* 47: 389 -394.

Trumper L, Monasterolo LA and Elías MM. (1996). Nephrotoxicity of acetaminophen in male Wistar rats: role of hepatically derived metabolites. J Pharmacol Exp Ther., 279(2): 548-554.

Umoh UF, Thomas PS, Essien EE, Okokon JE, De Leo M, Ajibesin KK, Flamini G, and Eseyin OA. (2021). Isolation and characterization of bioactive xanthones from *Hippocratea africana* (Willd.)Loes.ex Engl. (Celastraceae). J Ethnopharmacol., 280: 114031.