HISTO-MORPHOLOGICAL EVALUATIONS OF THE CEREBELLUM IN DIHYDROCODEINE-TREATED RAT MODELS

[1]Thomas MA, [2]Akunna GG, [3]Ojo GB, [3]Kolawole, DO., [4]Irozuoke A., [5]Adetunji Fatima Hamzat, [3]Ojo J

[1]Department of Anatomy, Lead City University, Ibadan, Oyo State, Nigeria
[2]Department of Anatomy, Benue State University, Makurdi, Benue State, Nigeria
[3]Department of Anatomy, Bowen University, Iwo, Osun State, Nigeria[4]Department of Anatomy, Baze University, Abuja FCT, Nigeria
[5]Department of Anatomy, College of Health Sciences, University of Ilorin, Kwara State Nigeria.
[2]Corresponding Author: Dr AKUNNA GG ggakunna@gmail.com

Abstract

The dihydrocodeine and dihydrocodeine-containing drugs have been used by opioid addicts as a substitute to heroin as it has similar metabolic pathways as codeine. In this study we assessed the histopathological and deleterious effects of DHC on the cerebellum of rats using different staining methods. Thirty-six Adult male Wistar weighing (110 ± 10 g) were randomly divided into three (3) groups (A-C, of 12 rats each). Group A served as the control (treated with 5ml/kg normal saline), group B and C rats received 15 mg/kg and 25mg/kg dihydrocodeine receptively via oropharyngeal cannula for 14days. The rats were sacrificed, and the cerebellum was processed. Each section was stained with Haematoxylin and eosin (H&E), Cresyl fast violet, and Luxol fast blue for basic and advanced histological demonstrations. Results showed a significant ($p<0.05$) decrease in body weight of group B (117.42±6.50) and group C (146.17±12.62) when compared to control group (117.42±6.50). Sections from the DHC-induced group had extensive areas of neuronal loss and showed evidence of several degeneration of Purkinje cell, fusiform-shaped nuclei of neuronal cell bodies that were centrally positioned. The cytoplasm seemed eosinophilic. Varying degree of cellular modifications including pyknosis of the nuclei were observed when compared with negative control group (group A). These were evident by a significant ($p<0.05$) decrease in molecular layer thickness, number of purkinje and granular cells of group B when compared to control group. Dihydrocodeine has a deleterious effect on the cerebellar architecture of Wistar rats

Dihydrocodeine, Cerebellum, morphometry, Cresyl fast violet, and Luxol fast blue

INTRODUCTION

The opioid, dihydrocodeine (DHC), is an analgesic and an antitussive drug. Over the years, dihydrocodeine and dihydrocodeine-containing drugs were used by opioid addicts as a substitute to heroin as it has similar metabolic pathways as codeine (Fromm *et al.* 1995; Hufschmid *et al.* 1995). These include *O*-demethylation to dihydromorphine, formation of the corresponding 6- and/ or 3-*O*-glucuronides dihydrocodeine-6-*O*-, dihydromor- phine-3-*O*- and dihydromorphine-6-*O*-glucuronide, and *N* demethylation to nordihydrocodeine (fig. 1; Helmut *et al.*, 2002).

Although both DHC and codeine possesses antitussive and analgesic properties, it must be said however, that DHC differs in its chemical structure by the saturation of the double bond between C7 and C8 (fig. 1). (Derry *et al;* 2013; Peterson *et al.,* 2015).

The request for codeine remains high and has risen by approximately 27% over the last decade (INCB, 2012). It is gaining increasing importance as step 2 of the "analgesic ladder" originally proposed by the World Health Organization (1986) for the treatment of cancer pain. It has been reported that DHC began to replace codeine when it became available as a slow-release preparation (Wotherspoon *et al.,* 1991; Ilmar *et al.,* 1997; Peter *et al.,* 2019).

The abuse of DHC is increasing globally and this has been linked to the euphoria it presents to users especially in Africa (Abudu, 2008; Ekpang & Abuo, 2015; Mohamadi *et al.,* 2018; Kiunguyu, 2018; Victor *et al.,* 2020). Although common side effects of DHC includes drowsiness, nausea, immune system disorder, endocrine disorder, nervous system disorder, eye disorder, ear and labrynth disorder, cardiac disorder, renal and urinary disorder, DHC has been reported to affect neural parts like the cerebellum, prefrontal cortex, and cerebrum (Peter *et al.,* 2019, Victor *et al.,* 2020; Theresa *et al.,*2020). Melissa (2013) linked prefrontal cortex and cerebellum (emotional and social behavior, motor coordination center) maladies to opiod consumption. Prolonged use of opioids has also been associated to physiological and behavioral malfunctions (Stimmel & Kreek, 2000). While a healthy thyroid function is necessary for normal development of the brain and life-long cognitive function, abnormal changes in cerebellar circuitry could be detrimental to the processing of emotional responses (Reiman *et al.,* 2004; Konarski *et al.,* 2005; Ebtesam *et al.,* 2017).

Due to few available literatures on the extent of the histopathological consequence of misuse of opioid analgesic on the cerebellum (Peterson, 2015), this study was designed to assess the histopathological and deleterious effects of DHC on the cerebellum of rats using different staining methods (Cresyl violet and Luxol Fast Blue) and stereological principles and morphometry. This study could provide a quantitative insight to changes in the cerebellum, provide a numerical, reproducible scale of quantitative features like neurons myelin/myelinated axons and Nissl bodies and enhance sensitivity in detecting cerebellar histopathology post exposure to DHC (True, 1996).

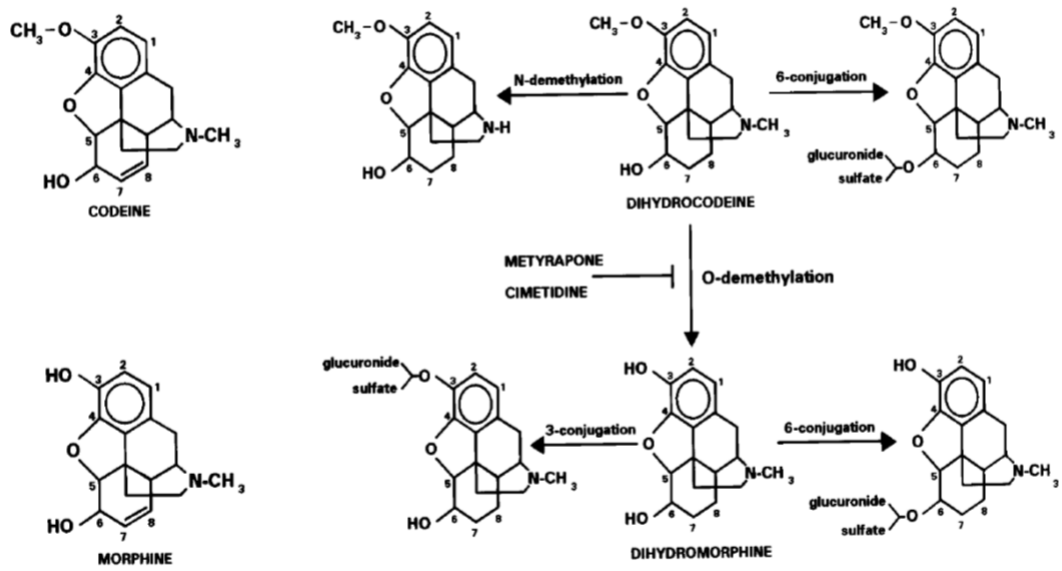

Fig. 1. Structure formulas of codeine, morphine and dihydrocodeine and the metabolic fate of dihydrocodeine. Metyrapone and cimetidine inhibit O-demethylation of dihydrocodeine by blocking the activity of cytochrome P-450.

(Helmut *et al.*, 2002)

Materials and Methods

Thirty-six Adult male Wistar weighing 110 ± 10 g/body weights were randomly divided into three (3) groups (A-C, of 12 rats each). Group A served as the control and the rats were treated with 5 ml/kg body weight of distilled water, group B received 15 mg/kg dihydrocodeine (Sigma-Tau Pharmaceuticals, Inc.) and group C were given 25mg/kg dihydrocodeine via oropharyngeal cannula. The duration of the study was for 14 days. The animals had access to rat chaw and water *ad libitum*. All procedures were carried out in accordance with the standard international guidelines on the use of animals for research (National Research Council, 2011). Approval for the study was obtained from the animal research ethical committee of Bowen University.

Animal sacrifice and Sample Collection

The rats were anesthetized intraperitoneally (Ketamine- 100mg/kg) and perfused transcardially with 0.1M Phosphate Buffer (pH 7.4) and 10% formalin in 0.1 M Phosphate Buffer (pH 7.4). The cerebellum was immediately harvested and fixated in 10% buffered formalin.

Histopathological and Morphometric Evaluations

The tissues were then dehydrated, embedded in paraffin and coronal sections (5µm) were obtained with rotator microtome. Each section was stained with Haematoxylin and eosin (H&E), Cresyl fast violet, and Luxol fast blue for basic and advanced histological demonstrations.

Morphometry

This was done as described by Bianco *et al.* (2015) using Image J software (version 1.46) Molecular and granular cell layers thickness were manually measured at 50 measurements per layer on 11 random

selected fields at 100x magnification. HE-stained sections were used for granule cell neuron density. Ten randomly selected fields were acquired at 400x magnification. Nuclei count was automatic using the "Analyze particles" instruction after thresholding. Density was expressed as granule cell neurons/10000 μm2. Linear density of the Purkinje neurons was quantified on ten randomly selected fields at 200x magnification for each anatomic-functional region. Purkinje neurons were counted (neurons/millimeters).

STATISTICAL ANALYSIS

The statistical analysis applied in this study express the values in form of their mean and standard deviation. The difference of the mean between each of the groups was analyzed using one-way ANOVA in comparison with the control using Ducan method at a 0.05 significance level.

RESULTS

Body Weight

As shown in Table 1, there was a difference ($p<0.05$) increase in weight of group B (109.33±3.77) and group C (125.16±6.58) rats post-DHC treatment when compared to the control rats (111.33±25.39). After the experiment, we observed a significant ($p<0.05$) decrease in body weight of group B (117.42±6.50) when compared to control group (117.42±6.50). However, there was no significant difference in body weight of group C (146.17±12.62) when compared to control group (117.42±6.50).

Table 1: Initial and final Body weight of experimental models

Groups	Initial Body Weight (g)	P VALUE	Final Body Weight (g)	P VALUE
Group A (control)	111.33±25.39	-	144.75±27.44	-
Group B (15mg/kg)	109.33±3.77**	0.788	117.42±6.50**	0.003
Group C (25mg/kg)	125.16±6.58**	0.063	146.17±12.62**	0.873

**represent significant increases or decreases at $p < 0.05$ when compared to control group (Group A). Values are means ± SD. n = 12 in each group

Histological Assessment

Three layers were observed on examination of the sections of the control rats (group A): an outer layer lightly stained with molecular markers, a middle Purkinje layer, and an inner granular layer. Results from group A rat showed normal Purkinje cells, and the histological cerebellar folia characteristics greatly contrast from the DHC group. They exhibited deeply stained and distributed basket cells in the molecular deposit of the cerebellum. The huge cell bodies of Purkinje cells had very pale nuclei and protruding nucleoli characterized by diverging dendrites, while

several small granular cells were compactly crammed in the inner granular layer. They were characterized by rounded dark nuclei and petite cytoplasm.

However, on examination, sections from the DHC-induced group (Group B and C) had extensive areas of neuronal loss and showed évidences of several degeneration of Purkinje cell, fusiform-shaped nuclei of neuronal cell bodies that were centrally positioned. The cytoplasm seemed eosinophilic. Varying degree of cellular modifications including pyknosis of the nuclei were observed when compared with negative control group (group A). In addition, sections from DHC group had vacuolation in their molecular layer. Aside from severed areas, focal regions of Purkinje cell loss were evident coupled with shrunken and irregularly delineated cells with extremely stained cytoplasm, and slight pyknotic nuclei.

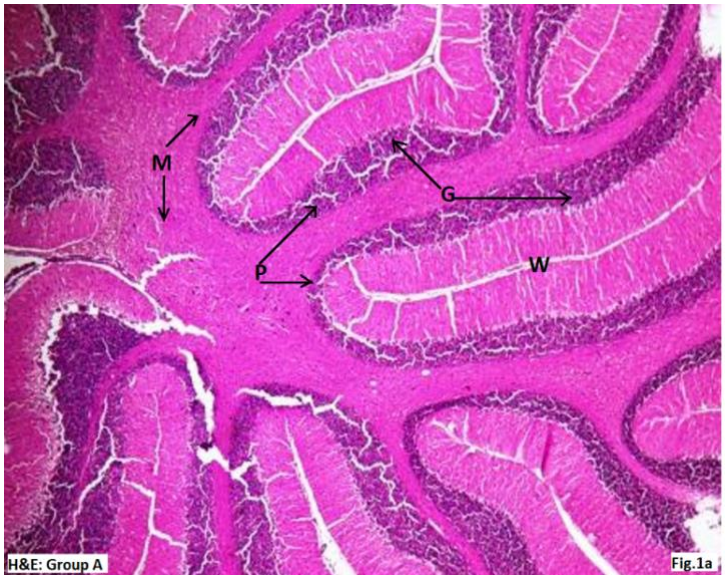



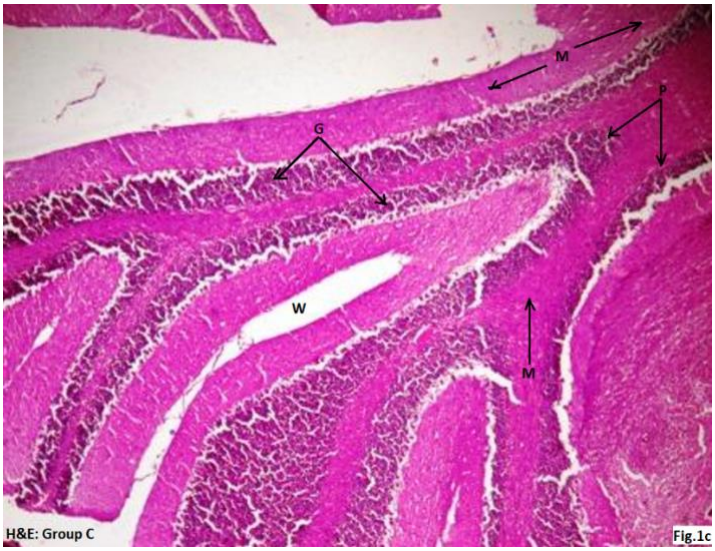

Figure 1a-c: Cross-section of cerebellum of group A (5ml/kg water), group B (15mg/kg DHC) and group C (25mg/kg DHC). M: Molecular layer; P: Purkinje layer; G: granular layer and W: white matter. H&E (x40).

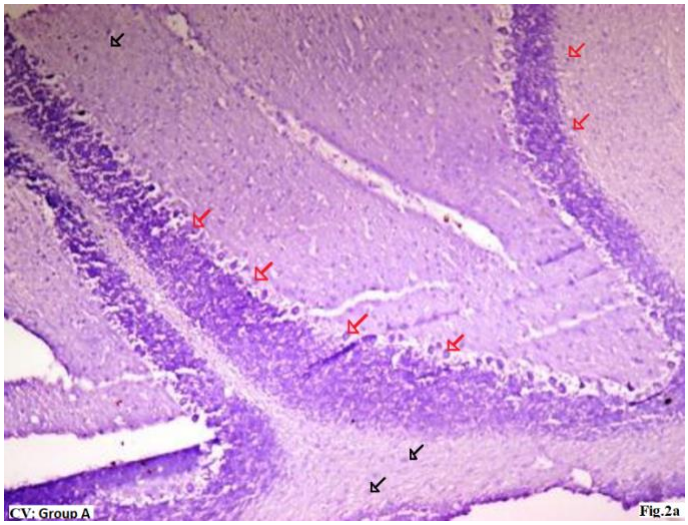

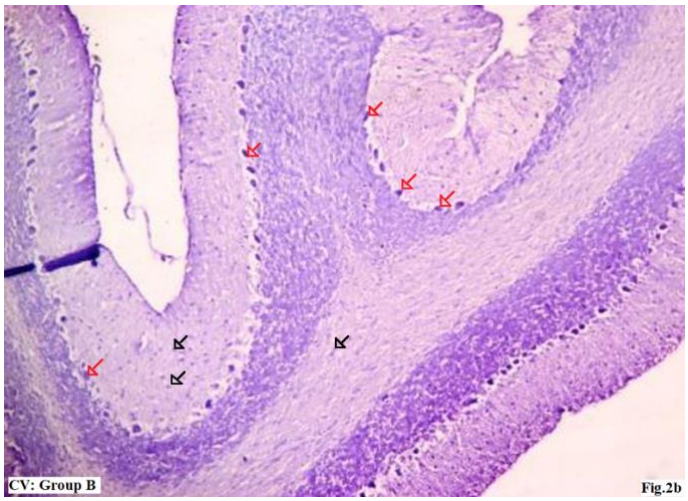

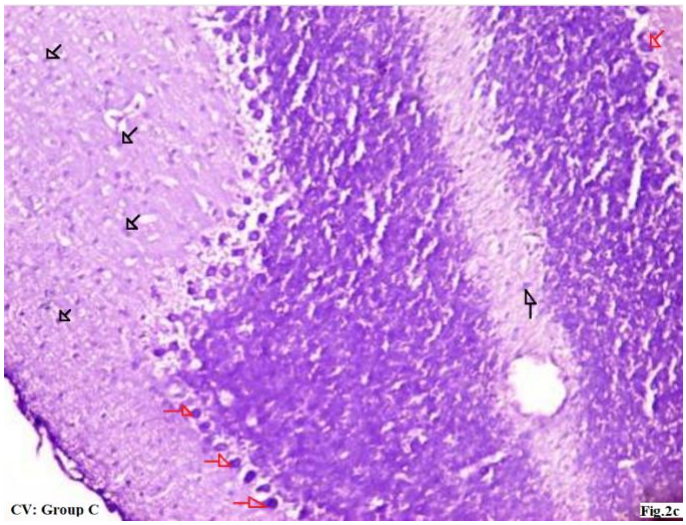

Figure 2a-c: Cross-section of cerebellum of group A (5ml/kg water), group B (15mg/kg DHC) and group C (25mg/kg DHC). Cresyl violet depicted cellular degenerations in terms of lightly stained condensed nissl substance, loss of nucleus and reduced number of purkinge cells (Red Arrow). Additionally, cells in the molecular and granular layer were reduced in number with small lighly stained cell bodies presenting chromatolysis. (black arrow) (x40).

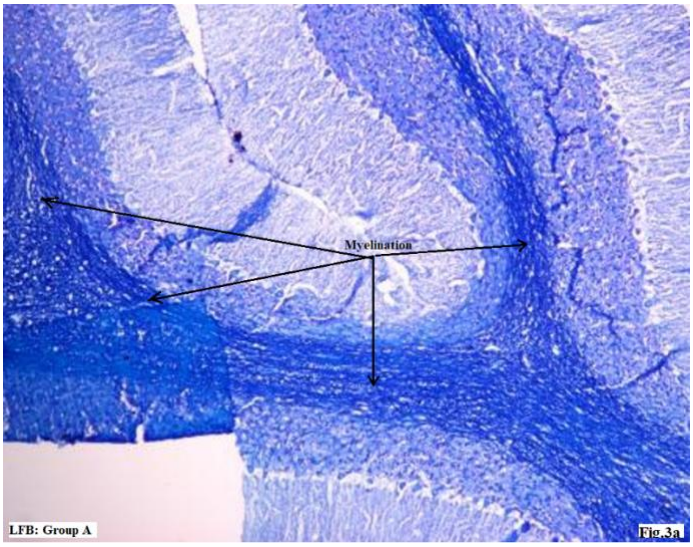

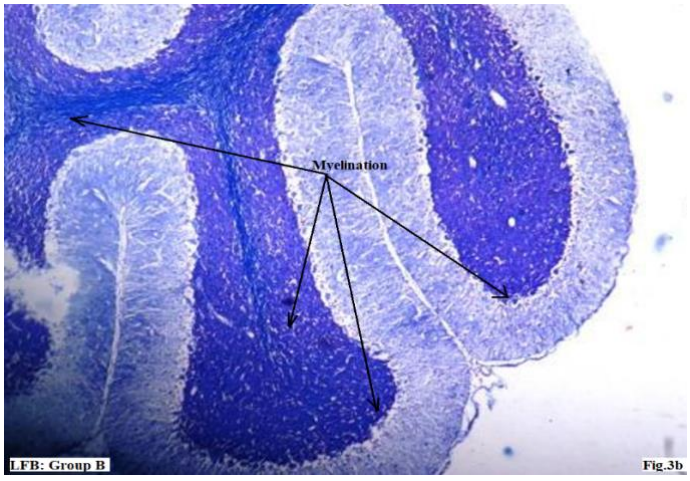

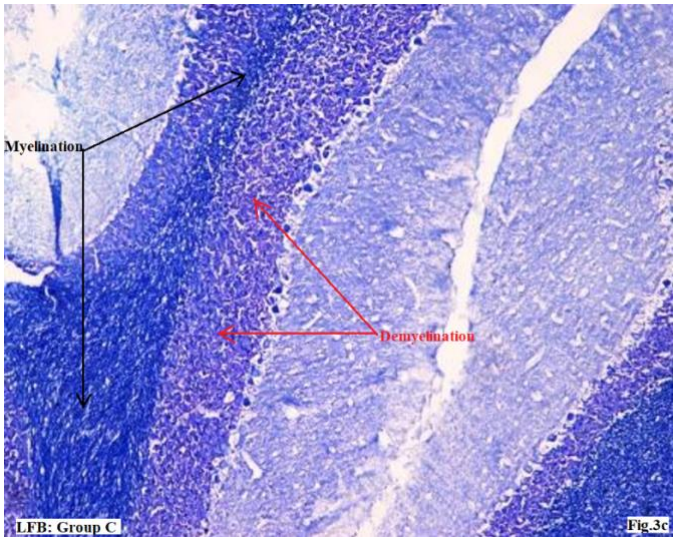

Figure 3a-c: Cross-section of cerebellum of group A (5ml/kg water), group B (15mg/kg DHC) and group C (25mg/kg DHC). Luxol Fast Blue depicted myelinations (Black Arrow) in the treatment groups except for some few demyelinations in group C (Red Arrow) (x40).

Morphometry

There was a significant ($p<0.05$) decrease molecular layer thickness, number of purkinje and granular cells of group B (221.45±62.3; 42.08±1.78 and 54.11±10.18 respectively) and group C (242.18±43.31; 33.92±0.90 and 57.92±0.90 respectively) when compared to control group (262.34±43.5; 49.92±1.08 and 86.01±2.03 respectively) (Table 2).

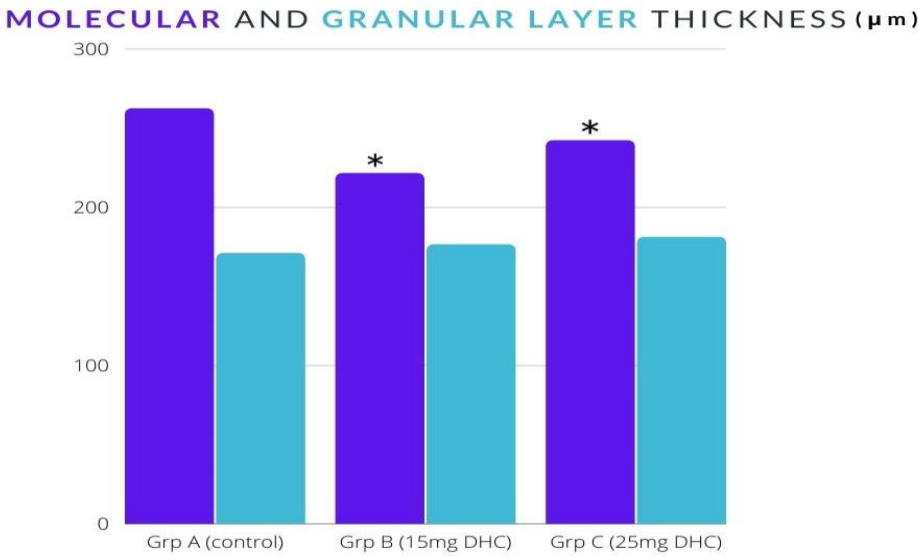

Figure 4: Result Showing the Molecular layer thickness**(**µm**)** and Granular layer thickness **(**µm**).** *represent significant increases or decreases in molecular and granular layers at $p < 0.05$ when compared to control (Group A). Values are means ± SD. n = 12 in each group.

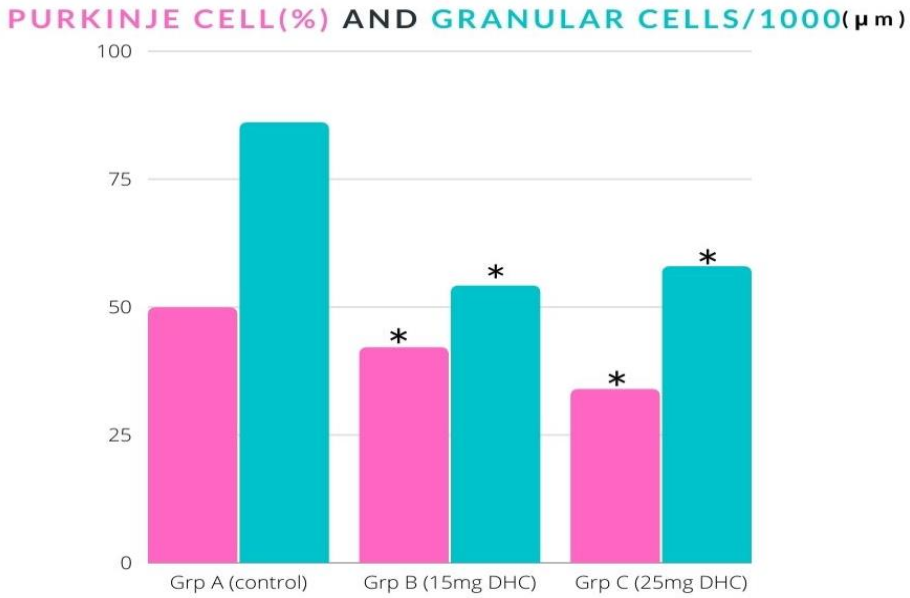

Figure 5: Result showing the number of Purkinje and granular cells. *represent significant increases or decreases in molecular and granular layers at $p < 0.05$ when compared to control (Group A). Values are means ± SD. n = 12 in each group.

DISCUSSION

Previously, the cerebellum has been classified to be involved only in motor function (Holmes, 1939) and motor learning (Bernard and Seidler, 2013). However, there is a growing literature suggesting that the cerebellum also contributes to non-motor behavior (Chen *et al.*, 2014; Schmahmann, 2018). Rightly so, what else can be said about the largest structure in the human brain in terms of sheer number of neurons (Buckner, 2011).

The cerebellum has an extremely high input-to-output axon ratio (Nitsche *et al.*, 2008; Buckner, 2011; Oldrati and Schutter, 2018). Inhibition and shifting ability have also been linked to it (Neau *et al.*, 2000; Ravizza and Ivry, 2019). Its posterior lobules have been implicated in this debate (Stoodley and Schmahmann, 2010; Buckner *et al.*, 2013; Maldonado *et al.*, 2019). However, it must be said that the extent of its involvement has not fully been elucidate even in human subjects. And one thing is sure, disruption of its circuitry by any organizational damage could deter the processing of emotional responses and results in momentous personality changes.

Programmed cell death in the cerebellum has been known to result from cytotoxic effect of various neurotoxins. Exposure to opioid hastened this likelihood. For instance, chronic morphine administration in rats has been linked to significant changes in the principal proteins involved in the apoptosis signalling (Peter *et al.*, 2019).

Employing morphometry in the evaluation of degenerative disorders is very promising and could afford an exciting involvement to cases with more subtle histological changes.

In this study, we evaluated the histopathological effect of DHC on the cerebellum using morphometry that proved

a useful ancillary tool in measuring cerebellar cellular populations.

There was an indication that DHC could cause cortico-cerebellar degeneration (loss of Purkinje neurons accompanied by a consequential reduction of granule cell neurons (Summers *et al.,* 1995).
The control groups of rats had normal Purkinje cells and histological cerebellar folia in addition to exhibiting deeply stained and distributed basket cells in the molecular deposit of the cerebellum with huge cell bodies of Purkinje cells with pale nuclei and protruding nucleoli characterized by diverging dendrites. Granular cells were compactly crammed in the inner granular layer and characterized by rounded dark nuclei and petite cytoplasm.

However, same cannot be said about DHC-induced group that had extensive areas of neuronal loss and showed evidence of several degeneration of Purkinje cell, fusiform-shaped and pyknotic nuclei of neuronal cell bodies with cytoplasm that seemed eosinophilic. These histopathological changes are in accordance with several other study (Summers *et al.,* 1995; Cartabuke *et al.*, 2006; Vandevelde *et al.,* 2012;).

The cerebellar pathology observed in this study might have been as a result of dysregulation of plasma membrane calcium ATPase (PMCA2). PMCA2 is a calcium pump expressed primarily in neurons and Purkinje cells (Stahl *et al.,* 1992; Stauffer *et al.,* 1997; Tachibana *et al.,* 2004; Michael *et al.,* 2007). This is in line with reports by Kozel *et al.* (1998) of an increase in the density of Purkinje neurons and a decrease in the density of granule cells, thickness of the molecular layer.
Cerebellar degeneration is commonly linked with reactive gliosis (Summers *et al.,* 1995; Vandevelde *et al.,* 2012; Bianco *et al.,* 2015; Peter *et al.,* 2019; Victor *et al.,* 2020; Theresa *et al.,*2020). It has been stated that that Purkinje cell death is "patterned" and topographically complex (Sarna and Hawkes, 2003).
Since the cerebellum shares physiological connections with all major functional divisions of the CNS.3, cerebellar pathology observed in this study might make clear in several ways. According to the theory by Allen and Courchesne (1998), it might lead to significant diminishing in a neurobehavioral function. While it seems strange that damage to the cerebellum does not affect activities known to activate it, we align with the proposed theory of cerebellar function. We are not suggesting that damage to the cerebellum is at the forefront. However, the likely contribution of cerebellar abnormalities to disorders characterized by non-motor symptoms can no longer be dismissed especially in DHC treated models. This theory might have given an insight and possible explanation for the behavioral and psychological changes associated with codeine abuse.
We conclude from the results obtained therein that Dihydrocodeine has a deleterious effect on the cerebellar architecture of Wistar rats.

REFERENCES

Abou, M.F., Fatoh, E., Farag, M.R., & Hussein, P.M (2014). Some Biochemical, Neurochemical, Pharmacotoxicological and Histopathological Alterations Induced by Long-term

Administration of Tramadol in Male Rats. International jouranal of pharmarcy and pharmaceutical sciences volume 4 (567-571)

Abudu, R. V. (2008). *Young people and drugs abuse: Biennial international conference on alcohol, drugs and society in africa*. https://doi.org/10.1.1.510.7128.

Allen G and Courchesne E (1998). The cerebellum and non-motor function: clinical implications Molecular Psychiatry 3, 207–210.

Bernard JA, Seidler RD (2013). Relationships between regional cerebellar volume and sensorimotor and cognitive function in young and older adults. Cerebellum. 12(5):721–37.

Bianco C, C Bombardi, G Gandini, A Gallucci, R Sirri, G Sarli and L Mandrioli, 2015. Quantitative pathology of canine cortico-cerebellar degeneration. Pak Vet J, 35(2): 248-250.

Buckner RL (2013). "The cerebellum and cognitive function: 25 years of insight from anatomy and neuroimaging". Neuron. 80 (3): 807–815.

Buckner RL, Krienen FM, Castellanos A, Diaz JC, Thomas Yeo BT (2011). The organization of the human cerebellum estimated by intrinsic functional connectivity. J Neurophysiol 106(5):2322–45.

Büttner, A., Weis, S (2006). Neuropathological alterations in drug abusers. *ForensSci Med Pathol* 2, 115–126 (2006).

Cartabuke RS. (2014). “Current practices regarding codeine administration among pediatricians and pediatric subspecialist”. Clinical pediatrics 53.1: 26-30.

Derry S, Karlin SM, Moore RA. (2013). single dose oral ibuprofen plus codeine for acute postoperative pain in adults. Cochrane Database of Systematic Reviews. Issue 3. Art. No.: CD010107.

Desmond JE, Gabrieli JD, Wagner AD, Ginier BL, Glover GH (1997). Lobular patterns of cerebellar activation in verbal working-memory and finger-tapping tasks as revealed by functional MRI. J Neurosci. 17(24):9675–85.

Doya K (1999). "What are the computations of the cerebellum, the basal ganglia and the cerebral cortex?". Neural Networks. 12 (7–8): 961–974.

Doya K (2000). "Complementary roles of basal ganglia and cerebellum in learning and motor control". Curr.Opin.Neurobiol. 10 (6): 732–739.

E K-H, Chen S-HA, Ho M-HR, Desmond JE (2014). A meta-analysis of cerebellar contributions to higher cognition from PET and fMRI studies. Hum Brain Mapp 35(2):593–615.

Ebtesam Mohammed AL Jehani1, Samar Alsaggaf, Wafaa S Ramadan and Soad Shaker Ali (2017).

Neuroprotective effects of thymoquinone against cerebellar histopathological changes in propylthiouracilinduced hypothyroidism in adult rats Tropical Journal of Pharmaceutical Research 16 (5): 1029-1037.

Ekpang, P. U., & Abuo, C. B. (2015). Relationship between drug abuse and psychosocial behaviours among adolescents' in senior secondary schools in cross river state,nigeria - counseling interventions. *European Journal of Business and Management, 7* (36), 151–159. https://doi.org/10.1.1.735.8614.

European Medicines Agency. (2013) "Assessment report for codeine containing medicinal products indicated in the management of pain in children". Procedure under Article 31 of Directive 2001/83/EC resulting from pharmacovigilance data Procedure number: EMEA/H/A-31/1342. London: European Medicines Agency

Frank B, Serpell M G, Hughes J, Matthews J N S, Kapur D. (2008) Comparison of analgesic effects and patient tolerability of nabilone and dihydrocodeine for chronic neuropathic pain: randomised, crossover, double blind study BMJ ; 336 :199.

Fromm, M. F., U. Hofmann, E. U. Griese & G. Mikus (1995) Dihydrocodeine: a new opioid substrate for the polymorphic CYP2D6 in humans. *Clin. Pharmacol. Therap.* 58, 374–382.

Helmut Schmidt, Stefan V. Vormfelde, Klaus Klinder, Ursula Gundert-Remy, Christoph H. Gleiter, Gisela Skopp, Rolf Aderjan and Uwe Fuhr. (2002) Affinities of Dihydrocodeine and itsMetabolites to Opioid Receptors. *Pharmacology & Toxicology* 91, 57–63.

Holmes G. The Cerebellum of Man. Brain (1939) 62(1):1–30. Available from: https://academic.oup.com/brain/article-lookup/doi/10.1093/brain/62.1.1

Hufschmid, E., R. Theurillat, U. Martin & W. Thormann (1995) Exploration of the metabolism of dihydrocodeine via determination of its metabolites in human urine using micellar electrokinetic capillary chromatography. *J. Chromatogr. B Biomed. Appl.* 668, 159–170.

Ilmar Jurna, Wolfgang KO¨ Men, Joseph Baldauf; Wolfgang Fleischer (1997). Analgesia by Dihydrocodeine Is Not Due to Formation of Dihydromorphine: Evidence from Nociceptive Activity in Rat Thalamus JPET 281:1164–1170.

INCB. "Comments on the Reported Statistics on Narcotic Drugs Austria" (2012): 73-93.

Kiunguyu, K. (2018), Africa: Codeine syrup addiction is an opioid

epidemic that is sweeping the African. Accessed; August 20, 2019.

Konarski JZ, McIntyre RS, Grupp LA, Kennedy SH (2005). Is the cerebellum relevant in the circuitry of neuropsychiatric disorders? J Psychiatry Neurosci; 30 (3): 178-186.

Kozel, P.J., R.A. Friedman, L.C. Erway, *et al.* (1998). Balance and hearing deficits in mice with a null mutation in the gene encoding plasma membrane Ca2+- ATPase isoform 2. J. Biol. Chem. 273: 18693–18696.

Leiner HC, Leiner AL, Dow RS (1989). Reappraising the cerebellum: What does the hindbrain contribute to the forebrain? Behav Neurosci. 103(5):998–1008.

Leiner HC, Leiner AL, Dow RS (1991). The human cerebro-cerebellar system: its computing, cognitive, and language skills. Behav Brain Res. 44(2):113–28.

Liu LW, Lu J, Wang XH, Fu SK, Li Q, Lin FQ. (2013) Neuronal apoptosis in morphine addiction and its molecular mechanism.Int J ClinExp Med. 1;6 (7):540-5.

Maldonado T, Goen JRM, Imburgio MJ, Eakin SM, Bernard JA (2019) Single session high definition transcranial direct current stimulation to the cerebellum does not impact higher cognitive function. PLoS ONE 14(10): e0222995. https://doi.org/10.1371/journal.pone.0222995

Manto, Mario; Mariën, Peter (2015). "Schmahmann's syndrome - identification of the third cornerstone of clinical ataxiology". Cerebellum & Ataxias. 2:2. PMC 4552302 . PMID 26331045.

Mariën P, Manto M (2016). The linguistic cerebellum. London, UK: Academic Press. pp. 337–351.

Marinus J. (2011). Clinical features and pathophysiology of complex regional pain syndrome. *Lancet Neurol.* 10, 637–648.

Melissa, L. (2013). Lil Wayne hospitalization: What the Hell is Sizzurp? The Daily Beast. https://www.thedailybeast.comAccessed on 23/ 08/2019.

Michael P. Kurnellas, Amanda K. Lee, Karolynn Szczepanowski, and Stella Elkabes (2007). Role of Plasma Membrane Calcium ATPase Isoform 2 in Neuronal Function in the Cerebellum and Spinal Cord. Ann. N.Y. Acad. Sci. 1099: 287–291.

Mohamadi, A., Chan, J. J., Lian, J., Wright, C. L., Marin, A. M., Rodriguez, E. K., von Keudell, A., & Nazarian, A. (2018). Risk factors and pooled rate of prolonged opioid use following trauma or surgery: A Systematic review and meta-(Regression) Analysis. *The Journal of Bone and Joint Surgery. American Volume. 100 (15): 1332–1340.*, *100*(15), 1332–

1340. https://doi.org/10.2106/JBJS.17.01239.

Neau J-P, Anllo EA, Bonnaud V, Ingrand P, Gil R (2000). Neuropsychological disturbances in cerebellar infarcts. Acta Neurol Scand. 102(6):363–70.

Nitsche MA, Cohen LG, Wassermann EM, Priori A, Lang N, Antal A, et al. (2008) Transcranial direct current stimulation: State of the art. Brain Stimul. 1(3):206–23.

Oldrati V, Schutter DJLG (2018). Targeting the Human Cerebellum with Transcranial Direct Current Stimulation to Modulate Behavior: a Meta-Analysis. The Cerebellum 17(2):228–36.

Peter U.A, Nosa T.O, Erabor T, Henry E.A, Eze C., Okoyeocha OME. (2019). Codeine and its Histopathological Effect on Brain of Albino Rats: An Experimental Study ACTA SCIENTIFIC NUTRITIONAL HEALTH 3:2

Peterson GM. (2005) "Selecting nonprescription analgesics". American Journal of Therapeutics 12: 67-79.

Peterson GM. "Selecting nonprescription analgesics". *AmericanJournal of Therapeutics* 12 (2005): 67-79.

Rapoport M, van Reekum R, Mayberg H (2000). The Role of the Cerebellum in Cognition and Behavior. J Neuropsychiatry Clin Neurosci 12(2):193–8.

Ravizza SM, Ivry RB (2019). Comparison of the Basal Ganglia and Cerebellum in Shifting Attention Available from: https://www.mitpressjournals.org/doi/pdfplus/10.1162/08989290151137340

Reiman EM, Chen K, Alexander GE, Caselli RJ, Bandy D, Osborne D, Saunders AM, Hardy J (2004). Functional brain abnormalities in young adults at genetic risk for late-onset Alzheimer's dementia. Proc Natl Acad Sci. 101(1): 284-9.

Sarna JR and R Hawkes (2003). Patterned Purkinje cell death in the cerebellum. Prog Neurobiol, 70: 473-507.

Schmahmann J, Sherman JC (1998). The cerebellar cognitive affective syndrome. Brain 121(4):561–79.

Schmahmann JD (2018). The cerebellum and cognition. Neurosci Lett 62–75.

Stahl, W.L., T.J. Eakin, J.W. Owens, Jr., *et al.* (1992). Plasma membrane Ca(2+)- ATPase isoforms: distribution of mRNAs in rat brain by in situ hybridization. Brain Res. Mol. Brain Res. 16: 223–231.

Stauffer, T.P.,D. Guerini, M.R.Celio& E. Carafoli. (1997). Immunolocalization of the plasma membrane Ca2+ pump isoforms in the rat brain. Brain Res. 748: 21–29.

Stimmel, B., & Kreek, M. J. (2000). Neurobiology of addictive behaviors and its relationship to

methadone maintenance. *Mt Sinai Journal of Medicine, 67*(5-6), 375–380.

Stoodley CJ (2012). The cerebellum and cognition: Evidence from functional imaging studies. Cerebellum. 11(2):352–65.

Stoodley CJ, Schmahmann JD (2010). Evidence for topographic organization in the cerebellum of motor control versus cognitive and affective processing. 46(7):831–44.

Summers BA, JF Cummings and A de Lahunta, 1995. Hereditary, familial, and idiopathic degenerative diseases. In: Veterinary neuropathology (Summers BA, Cummings JF, de Lahunta A, eds): Mosby-Year Book, St Louis, USA, pp: 208-350.

Tachibana, T., H. Ogura, A. Tokunaga, *et al.* (2004). Plasma membrane calcium ATPase expression in the rat spinal cord. Brain Res. Mol. Brain Res. 131: 26–32.

Vandevelde M, RJ Higgins and A Oevermann (2012). Degenerative diseases. In: Veterinary Neuropathology. Essentials of theory and practice (Vandevelde M, Higgins RJ, Oevermann A, eds): Wiley-Blackwell, Ames, USA, pp: 157-192.

Victor B. Archibong, Theresa B. Ekanem, Anozeng O. Igiri, Ann M. Lemuel, Ibe M. Usman, Akeem A. Okesina and Nsisong J. Obosi (2020) Immunohistochemical studies of codeine medication on the prefrontal cortex and cerebellum of adult Wistar rats *Cogent Medicine* 7: 1824390.

Wotherspoon, H.A., Kenny, G.N.C., Mcardle, C. S. (1991). Analgesic efficacy of controlled release dihydrocodeine. Anaesthesia 46: 915–917.