Histo-Pathology Of Some Internal Organs Of Broiler Chickens Infected With *Salmonella enteritidis* And Treated With Methanol Extract Of *Phyllanthus amarus'* Leaves

Unigwe Robinson Cyprian[1*], Esan Oluwaseun Olanrewaju[2], Ukwueze Chigozie Stanley[3] and Egwu Lawrence Uchenna[1]

[1]Department of Veterinary Biochemistry and Animal Production, Michael Okpara University of Agriculture, Umudike, Abia State, Nigeria
[2]Department of Veterinary Medicine, University of Ibadan, Oyo State, Nigeria
[3]Department of Veterinary Medicine, Michael Okpara University of Agriculture, Umudike, Abia State, Nigeria

https://doi.org/10.54117/jcbr.v2i2.13

Submitted: Jan 20, 2022; Accepted: March 1, 2022; Published online: April 30, 2022
*Correspondance email: robinsonunigwe@gmail.com, +2348037707965

Abstract

A 21 d study was carried out to determine the histo-architectural defects associated with spleen, kidney, liver, heart and intestine of *Salmonella enteritidis*-infected broiler chickens treated with methanol extract of *Phyllanthus amarus'* leaves. Sixty (60) 5-week old unsexed Arbor acre broiler chickens on deep litter system were used for the study. They were allotted into 4 groups of T_1 = distilled water (control), T_2 = *Salmonella enteritidis* (SE) (1×10^7 CFU/mL, *per os*), T_3 = SE + *P. amarus* (150 mg/kg), and T_4 = SE + enrofloxacin (10 mg/kg, *per os*) in a completely randomized design and replicated thrice with 5 birds/replicate. One hour prior to inoculation of SE, T_3 and T_4 received *P. amarus* and enrofloxacin respectively which continued till expiration of study, whereas T_1 and T_2 received distilled water and SE respectively via the oral route. At the end of study, a bird per replicate was randomly sampled of the spleen, kidney, liver, heart, and intestine for histopathological examination. There were no observable lesions on T_1 plates. Meanwhile, the liver showed multifocal hepatocellular coagulation necrosis, and inflammation (T_2), moderate atrophy of hepatic plates (T_3) and hepatocellular atrophy, coagulation necrosis and inflammation (T_4). Other pathological lesions were seen in T_2 of all organs due to effect of SE and T_4 of the intestine that showcased moderate villi atrophy and cryptal necrosis. This showed that *P. amarus* was able to alleviate toxic manifestations occasioned by SE inoculation except in the liver where the lesion was however moderate.

Keywords: Broiler chicken, pathology, *Phyllanthus amarus* leaf, visceral organs

Running title: Pathology of *Salmonella enteritidis*-infected broiler chickens treated with *Phyllanthus amarus* extract

Introduction

The latent destruction or impairment of internal organs by indiscriminate consumption of herbal supplements or drugs has necessitated the need to be circumspect in their use. There is also a need for thorough investigation into their effect on

the visceral organs since detoxification of the body is a sole function of these indispensable organs. Herbal medicines are believed to be safer than synthetic medicine because phytochemicals in the plant extract target its biochemical pathways (Sandigawad, 2015).

Phyllanthus amarus is an ethnobotanical plant that is distributed in almost all tropical countries and regions including America, India and Nigeria (Adjene and Nwose, 2010). Gafar *et al.* (2012), Peters *et al.* (2015) and Sangeeta *et al.* (2017) have demonstrated the presence of some compounds that aid the actions of *P. amarus* to include alkaloids, flavonoids, hydrolysable tannins, major lignans, polyphenols, oxalate, phytate, hydrogen cyanide and nitrate. Some of these compounds have their usefulness when used moderately but elicit toxic effects when abused whereas some are anti-nutrients that impart negatively on the internal organs and general wellbeing of individual animals. Species of these animals could also be factored in since metabolic enzymes that aid biotransformation and subsequent elimination of these compounds are not equally given to all species. Due to these reasons, safety of herbal drugs is still issue of concern the world over (Calixto, 2000; Calapai, 2008).

This plant has been widely used by traditional medicine practitioners for the treatment of a wide variety of ailments (Calixto *et al.*, 1998; Grieve, 2008) with various claims that it treats liver diseases (Kamble *et al.*, 2008), gastroprotective activity, lowers blood pressure (Amonkan *et al.*, 2013) and anti-inflammatory activities (Ilangkovan *et al.*, 2015; Harikrishnan *et al.*, 2018). Due to the many applications of *P. amarus* plant in ethnomedicine, there is the need to investigate the effect on the histo-architecture of some visceral organs before using it in poultry production.

Materials and Methods

Experimental site and ethical consideration

The experiment was carried out at the Poultry Unit of the student's project site at the Federal College of Animal Health and Production Technology, Moor Plantation, Ibadan, Oyo State, Nigeria. Ibadan is located approximately on longitude 3° 5᾽ to 4° 36' E and latitude 7° 23᾽ to 7° 55' N (Oladele and Oladimeji, 2011). Ibadan has a tropical wet and dry climate, with a lengthy wet season. It has mean total rainfall of 9,233.60 mm, mean maximum and minimum temperatures of 39.8 °C and 22.5 °C respectively (Egbinola and Amobichukwu, 2013) and relative humidity of 74.55%. Ethical conditions governing the conduct of experiments with life animals were strictly observed as stipulated by Ward and Elsea (1997). The experimental protocol was approved by the College's ethical committee for the use of animals for experiment.

Collection and extraction of *Phyllanthus amarus* and sourcing of *Salmonella enteritidis*

The test plant used for this project is *Phyllanthus amarus* (Stone breaker). Code of ethics of the International Society of Ethnobiology (2008) was followed in identifying the plant. The leaves were collected from the school's botanical garden. The harvested fresh leaves were washed, rinsed with distilled water and air dried under shade until they were crispy to touch, while still retained their green colour. The leaves were ground with domestic electric grinding machine (Sonik® Model SB-464) to produce *P. amarus* leaf meal. The *P. amarus*

leaf meal was subjected to 80% methanol extraction using technique described by Handa *et al*. (2008). *Salmonella enteritidis* was obtained and transported from Fish and Wild Life laboratory of the Department of Veterinary Medicine, University of Ibadan, to the site of the study in a cold pack as described by Wolking (2013).

Birds, management and design

Sixty (60) day-old unsexed Arbor acre broiler chicks were used for the study. Prior to the arrival of the birds, the pens were cleaned and washed with detergent solutions. Disinfection of the pen was done using saponated cresol (Lysol®), and the pen was left unstocked for one week and the floor litter laid to $5cm^3$ with wood shavings. On arrival of the chicks, anti-stress solution (mixture of water, glucose and multivitamin) was served as well as normal feed (Top® starter feed, 22% crude protein (CP), 2800 kcal/kg metabolizable energy) and clean drinking water on *ad libitum* basis. Routine vaccinations (Newcastle disease vaccine (NDV) intra-ocular (i/o), Lasota and Infectious bursal disease (IBD)) were administered accordingly during the two weeks of acclimatization. IBD vaccine was repeated on day fourteen. After acclimatization, the birds were allocated to four treatments in a completely randomized design. The experimental dosing and groupings were as stated hereunder:

T_1 = distilled water (control), T_2 = *Salmonella enteritidis* [SE] inoculated (1×10^7 CFU/mL, per os (PO)), T_3 =SE inoculated + *P. amarus* (150 mg/kg), and T_4 = SE inoculated + enrofloxacin (10 mg/kg). They were replicated thrice with each replicate having 5 birds and SE (1×10^7 CFU/mL, PO) was inoculated at 5 wks of age. One hour prior to per os inoculation of SE, T_3 and T_4 received *P. amarus* (150 mg/kg) and enrofloxacin (10 mg/kg) in drinking water respectively. There was continuous administration of *P. amarus* and enrofloxacin for another 4 days (ie; 5 days in all) in T_3 and T_4. Finisher Top feed® (19% CP, 3200 kcal/kg) was given by 7 am and 5 pm daily whereas clean borehole water was supplied *ad libitum* throughout the experimental duration of 21 days under standard environmental conditions (a 12 h light and 12 h darkness cycle). Also, coccidiostat was given when the birds showed clinical signs of coccidiosis at week four.

Histo-pathological preparation

A bird per replicate was randomly selected, sacrificed humanely through cervical dislocation after stunning, at the Veterinary Pathology/Microbiology Laboratory, University of Ibadan. The birds were eviscerated of spleen, kidney, liver, heart and intestine and were stored in buffered 10 % formalin for 24 hours before histo-pathological preparation.

Analyses

The histo-pathology plates were viewed by veterinary pathologists of the Department of Veterinary Pathology, University of Ibadan, Nigeria, for lesions' detection and interpretations as described by Neel *et al*. (2007).

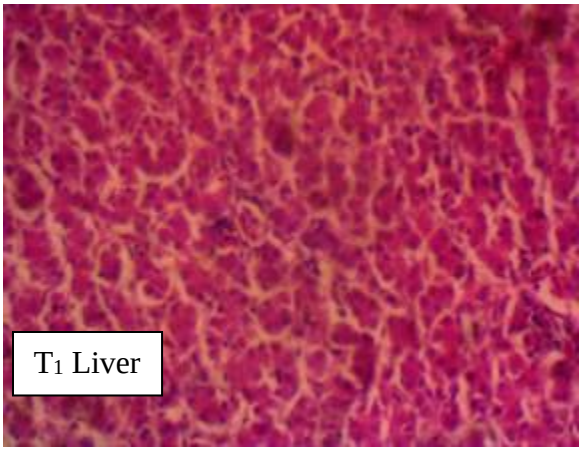

Figure 1: There is no observable lesion (H&E, ×400)

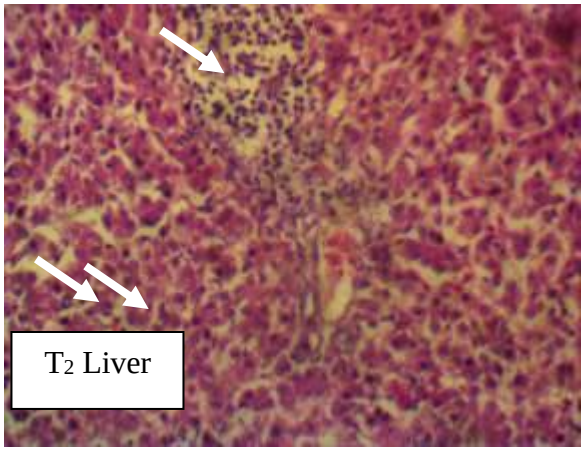

Figure 2: There is multifocal hepatocellular coagulation necrosis and inflammation (arrow). (H&E, ×400)

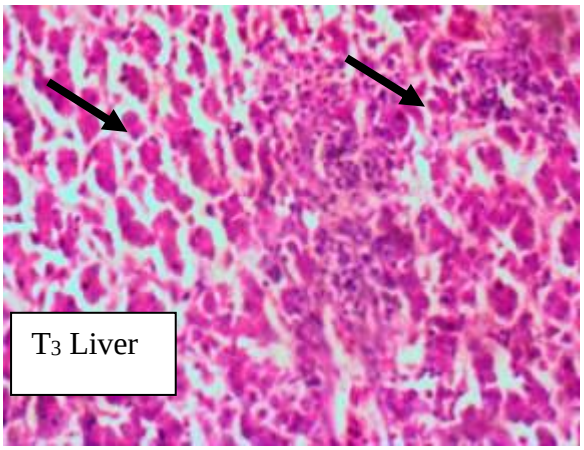

Figure 3: There is moderate atrophy of hepatic plates (arrows) (H&E, ×400)

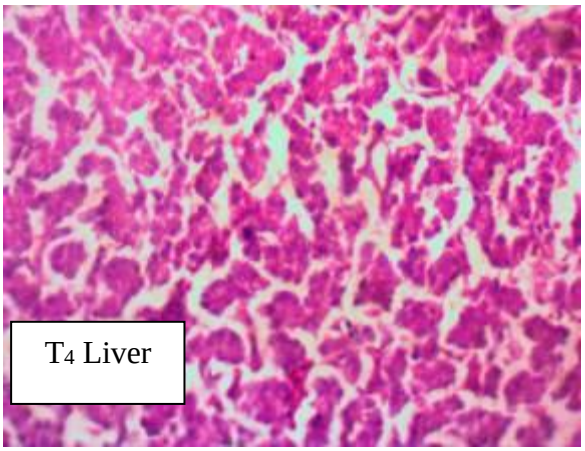

Figure 4: There is hepatocellular atrophy, coagulation necrosis and inflammation (H&E, ×400)

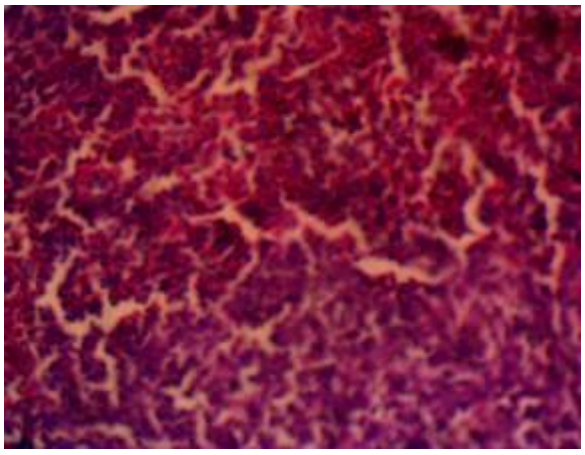

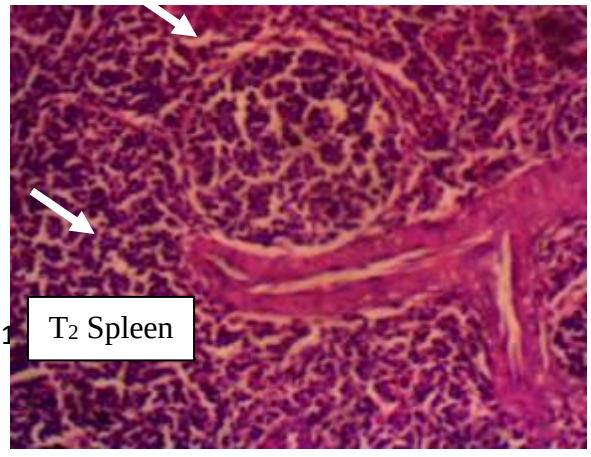

T_1 Spleen

Figure 5: There is no observable lesion (H&E, ×400)

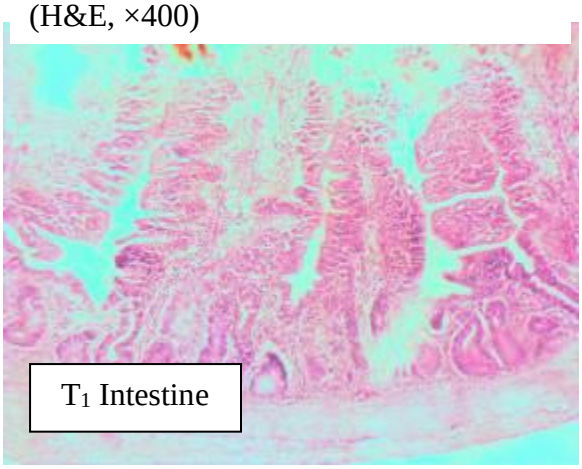

Figure 7: There is no observable lesion (H&E, ×400)

Figure 6: There is moderate lymphoid follicular hyperplasia (arrow) (H&E, ×400)

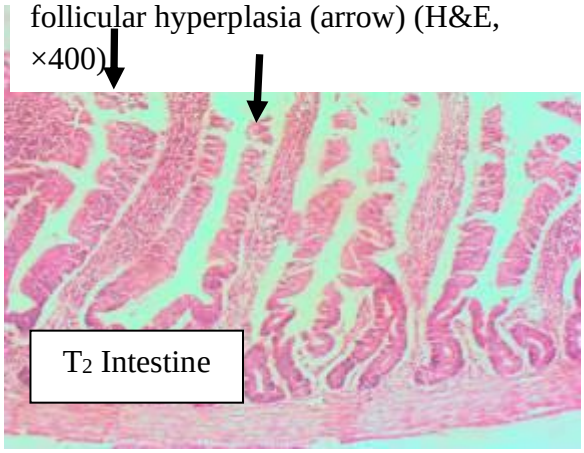

Figure 8: There is denudation of villi tips due to sloughing of enterocytes (arrows). (H&E, ×400)

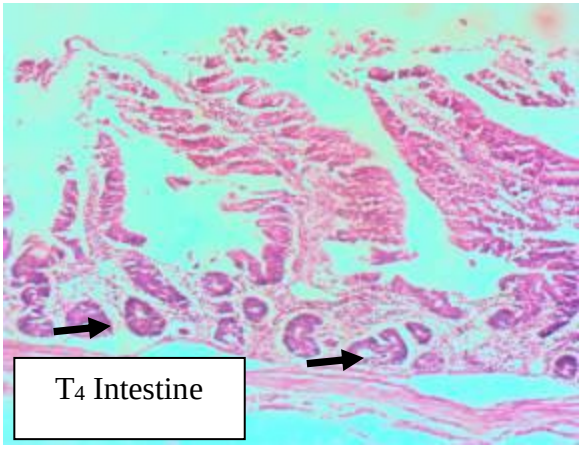

Figure 9: There is moderate villi atrophy, cryptal cell necrosis and inflammation (arrow). (H&E, ×400)

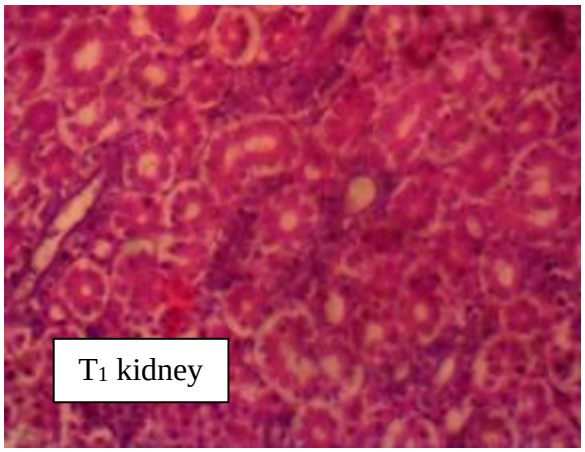

Figure 10: There is no observable lesion. (H&E, ×400)

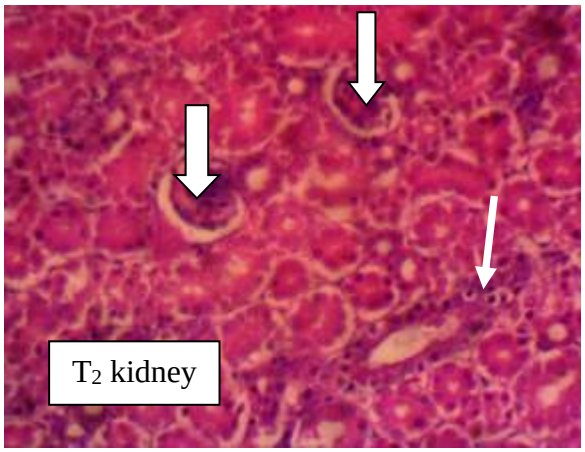

Figure 11: There are patchy tubular epithelial coagulation necrosis, perivascular inflammation (arrow). (H&E, ×400)

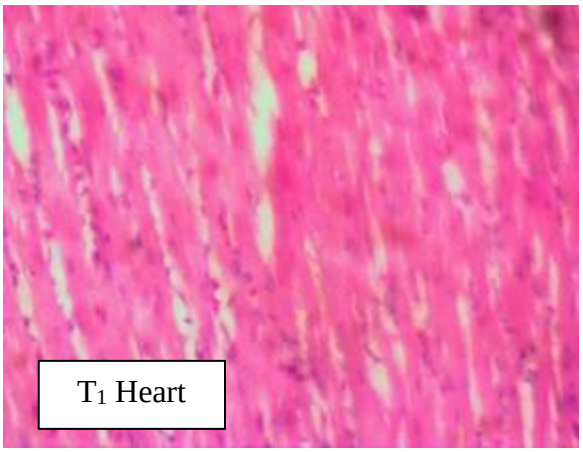

Figure 12: There is no observable lesion. (H&E, ×400)



Figure 13: There is myofibre degeneration and necrosis with inflammatory cellular infiltrates (arrows). (H&E, ×400)

Legend: H&E = haemotoxylin and eosin

Results and Discussion

There was no observable lesion in the T_1 (control) visceral organs (liver, spleen, intestine, kidney and heart). Meanwhile, the liver showed multifocal hepatocellular coagulation necrosis and inflammation, moderate atrophy of hepatic plates and hepatocellular atrophy, coagulation necrosis and inflammation in T_2, T_3 and T_4 respectively. Probably the *Salmonella enteritidis* has predilection for liver no wonder the observable lesions but it was assuaged by the administration of *P. amarus* hence the effect on the liver was only moderate (T_3) but not the same in T_4 possibly because enrofloxacin has hepatotoxic effect. However, the moderate atrophy of hepatic plates correlates with the findings of Adedapo *et al.* (2005) and Igwe *et al.* (2007) that *P. amarus* has toxic potentials to the liver and increases hepatic cell function respectively. Contrary to the result of the present study, Srirama *et al.* (2012), Kandhare *et al.* (2013), Kushwaha *et al.* (2013), and Hunaleyo *et al.* (2017) reported hepatoprotective property of the plant. With respect to the spleen, it was only T_2 that had moderate lymphoid follicular hyperplasia whereas other treatments had no observable lesions. Since the spleen filters the blood (Tarantino *et al.*, 2011) as part of the immune system, it could have activated infection-fighting leucocytes that possibly caused the moderate lymphoid follicular hyperplasia since it has been established that bacterial infection causes enlargement of the spleen (Couto and Gamblin, 2000). The intestine had no observable lesions in T_1 and T_3 but demonstrated varied lesions including denudation of villi tips due to sloughing of enterocytes in T_2 and moderate villi atrophy, cryptal cell necrosis and inflammation in T_4. The *P. amarus* in T_3 could have neutralized the *S. enteritidis* since it has been observed to have antimicrobial property by some researchers (Oluwafemi and Debiri, 2008; Adegoke and Adebayo-Tayo, 2009a, 2009b; Ushie *et al.*, 2013; Oluboyo *et al.*, 2016). The toxic effect on the liver could have been occasioned by alkaloids and lots of other antioxidants contained by *P. amarus* (Adomi *et al.*, 2017; Sangeeta *et al.*, 2017; Meena *et al.*, 2018) which is consistent with the notion that antioxidants may be associated with toxicities, particularly when arbitrarily consumed (Miller *et al.*, 2005). The kidney likewise had no observable lesions in all the treatments excepting T_2 where there was patchy tubular epithelial coagulation necrosis and perivascular inflammation. The *S. enteritidis* in circulation could have been filtered into the renal tubules resulting to inflammatory reaction and necrosis. With respect to kidney, the result contradicts the reports of Adedapo *et al.* (2005) and Manjrekar *et al.* (2008) whose experiments using wistar rats recorded necrosis and protein casts in the renal tubules. This might be due to the high doses of *P. amarus* they used. Similarly, only T_2 (Figure 13) showed observable lesions in the heart characterized by myofibre degeneration and necrosis with inflammatory cellular infiltrations. The results in other organs but liver, in this present study showed that *P. amarus* has no deleterious effect. This has been corroborated by reports of other researchers who found no histopathological changes associated with the plant (Patel *et al.*, 2011; Jantan *et al.*, 2014; Ilangkovan *et al.*, 2015; Harikrishnan *et al.*, 2018).

Conclusion

The results of this present study have shown that *P. amarus* has hepato-protective property at lower dose whereas effects generally are dose-dependent no wonder there was moderate atrophy of the hepatic plates but not in T_2 and T_4 where there were profound toxicities. It also showed reparative property to the pathologic effects of *S. enteritidis* in the spleen, intestine, kidney and heart, hence there were no visible lesions unlike T_2.

Acknowledgement

We want to appreciate Solomon Zacchaeus Olamilekan and Dorcas Abosede Adeyemi for their invaluable commitment at feeding the experimental birds whereas Adeniran Onaolapo Adeleke and Matthew Oluwatoyin Ojo ensured that biosecurity and cleanliness around the poultry house were at top notch during the study. We also extend our gratefulness to Dr Popoola Moshood for his assistance in the analysis of the data.

Conflict of interest

The authors declare no conflict of interest.

References

Adedapo AA, Adegbayibi AY, Emikpe BO (2005). Some clinico-pathological changes associated with the aqueous extract of the leaves of *Phyllanthus amarus* in rats. Phytotherapy Research 19, 971–976.

Adegoke AA, Adebayo-Tayo BC (2009a). Antibacterial Activity and Phytochemical analysis of Leaf Extracts of *Lasienthera africanum*. African Journal of Biotechnology 8(1), 077-080.

Adegoke AA, Adebayo-Tayo BC (2009b). Phytochemical Composition and Antimicrobial Effects of *Corchorus olitorius* Leaf Extracts on Four Bacterial Isolates. Journal of Medicinal Plants Research 3(3), 155-159.

Adjene JO, Nwose EU (2010). Histological effects of chronic administration of *Phyllanthus amarus* on the kidney of adult Wistar rat. North American Journal of Medical Sciences 2(4), 193–195.

Adomi PO, Owhe-Ureghe UB, Asagba SO (2017). Evaluation of the toxicity of *Phyllanthus amarus* in wistar albino rats. African Journal of Cellular Pathology 8, 27-35.

Amonkan AK, Kamagate M, Yao ANR, Konan AB, Kouame MN, Koffi C, Kati C, Die-Kakou H (2013). Comparative Effects of Two Fractions of *Phyllantus amarus* (Euphorbiaceae) on the Blood Pressure in Rabbit. Greener Journal of Medical Sciences 3(4), 129-134.

Calapai G (2008). European Legislation on Herbal Medicines: A Look into the Future. Drug Safety 31, 428–431.

Calixto JB, Santos ARS, Filbo VC, Yune RA (1998). A Review of the plants of the genus *Phyllanthus*: their chemistry, pharmacology, and therapeutic potential. John Wiley & Son, Inc. p. 225-258.

Calixto JB (2000). Efficacy, safety, quality control, marketing and regulatory guidelines for herbal medicines (phytotherapeutic agents). Brazilian Journal of Medical and Biological Research 33, 179–189.

Couto CG, Gamblin RM (2000). Non-neoplastic disorders of the spleen. In: Ettinger S, and Feldman E (eds): Textbook

of Veterinary Internal Medicine, ed 5. Philadelphia, WB Saunders, p. 1858-1860.

Egbinola CN, Amobichukwu AC (2013). Climate variation assessment based on rainfall and temperature in Ibadan, South-Western, Nigeria. Journal of Environment and Earth Science 3(11), 32-45.

Gafar MK, Itodo AU, Senchi DS (2012). Nutritive and anti-nutritive compositions of *Chanca piedra* (stone breaker). Food and Public Health 2(2), 21-27.

Grieve M (2008). Dandelion (*Taraxacum officinale* WEBER). A modern herbal. Botanical.com. p. 1-10.

Handa SS, Khanuja SPS, Longo G, Rakesh DD (2008). Extraction technologies for medicinal and aromatic plants, International centre for science and high technology. London, UK.

Harikrishnan H, Jantan I, Haque MA, Kumolosasi E (2018). Phyllanthin from *Phyllanthus amarus* inhibits LPS-induced proinflammatory responses in U937 macrophages *via* down-regulation of NF-κB/MAPK/PI3K-Akt signaling pathways. Phytotherapy Research 32, 2510–2519. doi: 10.1002/ptr.6190

Hunaleyo HF, Buratai LB, Mofio BM, Lawan HK, Abdulrahman AA (2017). Effects of *Phyllanthus amarus* on garlic-induced hepatotoxicity. Nigeria Journal of Health Sciences 17, 53-8.

Igwe CU, Nwaogu LA, Ujuwondu CO (2007). Assessment of the hepatic effects, phytochemical and proximate compositions of *Phyllanthus amarus*. African Journal of Biotechnology 6(6), 728-731.

Ilangkovan M, Jantan I, Mesaik MA, Bukhari SNA (2015). Immunosuppressive effects of the standardized extract of *Phyllanthus amarus* on cellular immune responses in Wistar–Kyoto rats. Drug Design, Development and Therapy 9, 4917. doi: 10.2147/DDDT.S88189

International Society of Ethnobiology (ISE) (2008). ISE Code of Ethics. Online: http://ethnobiology.net/code-of-ethics

Jantan I, Ilangkovan M, Mohamad HF (2014). Correlation between the major components of *Phyllanthus amarus* and *Phyllanthus urinaria* and their inhibitory effects on phagocytic activity of human neutrophils. BMC Complementary Alternative Medicine 14, 429. doi: 10.1186/1472-6882-14-429

Kamble MB, Dumbre RK, Ranyari VD (2008). Hepatoprotective studies of herbal formations. International Journal of Green Pharmacy 2: 147-151.

Kandhare AD, Ghosh P, Ghule AE (2013). "Protective effect of *Phyllanthus amarus* by modulation of endogenous biomarkers and DNA damage in acetic acid induced ulcerative colitis: role of phyllanthin and hypophyllanthin," Apollo Medicine 10(1), 87–97.

Kushwaha SK, Dashora A, Dashora N, Patel JR, Kori ML (2013). Acute oral toxicity studies of the standardized methanolic extract of *Phyllanthus amarus* Schum & Thonn. Journal of Pharmacy Research 67, 720–724. doi: 10.1016/j.jopr.2013.04.020

Manjrekar AP, Jisha V, Bag PP, Adhikary B, Pai MM, Hegde A (2008). Effect of *Phyllanthus niruri* Linn. treatment on liver, kidney and testes in CCl4 induced

hepatotoxic rats. Indian Journal of Experimental Biology 46, 514–520.

Meena J, Sharma RA, Rolania R (2018). A review on phytochemical and pharmacological properties of *Phyllanthus amarus* Schum. and Thonn. International Journal of Pharmaceutical Science and Research 9(4), 1377-86. doi: 10.13040/IJPSR.0975-8232.9(4).1377-86.

Miller ER, Pastor-Barriuso R, Dalal D, Riemersma RA, Appel LJ, Guallar E (2005). Meta-analysis: high-dosage vitamin E supplementation may increase all-cause mortality. Annals of Internal Medicine 142, 37–46.

Neel JA, Grindem CB, Bristol DG (2007). Introduction and evaluation of virtual microscopy in teaching veterinary cytopathology. Journal of Veterinary Medicine Education 34(4), 437-444. Doi:10.3138/jvme.34.4.437.

Oladele BM, Oladimeji BH (2011). Dynamics of urban land use changes with remote sensing: Case study of Ibadan, Nigeria. Journal of Geography and Regional Planning 4(11), 632-643.

Sandigawad AM (2015). Traditional Applications and Phytochemical Investigations of *Lonicera japonica* Thunb. International Journal of Drug Development and Research 7, 47-54.

Sangeeta D, Romana R, Muneesh K (2017). Phytochemistry and pharmacological properties of *Phyllanthus amarus* Schum: A review. The Pharma Innovation Journal 6(12), 169-172.

Srirama R, Deepak HB, Senthilkumar U (2012) "Hepatoprotective activity of Indian *Phyllanthus*." Pharmaceutical Biology 50(8), 948–953.

Oluboyo BO, Oluboyo AO, Kalu SO (2016). Inhibitory effects of *Phyllanthus amarus* extracts on the growth of some pathogenic microorganisms. African Journal of Clinical and Experimental Microbiology 17, 166–172.

Oluwafemi F, Debiri F (2008). Antimicrobial Effect of *Phyllanthus amarus* and *Parquetina nigrescens* on *Salmonella typhi*. African Journal of Biomedical Research 11, 215-219.

Patel JR, Tripathi P, Sharma V, Chauhan NS, Dixit VK (2011). *Phyllanthus amarus*: ethnomedicinal uses, phytochemistry and pharmacology: a review. Journal of Ethnopharmacology 138, 286–313. doi: 10.1016/j.jep.2011.09.040

Peters DE, Omeodu SI, Tege EB (2015). Effect of ethanolic leaves extract of *Phyllantus amarus* on cisplatin induced nephrotoxicity in albino rats. Journal of Applied Science and Environmental Management 19 (4), 811 – 816.

Tarantino G, Savastano S, Capone D, Colao A (2011). Spleen: A new role for an old player? World Journal of Enterology 17, 3776-3784. doi: 10.3748/wjg.v17.i33.3776.

Ushie O, Neji P, Etim E (2013). Phytochemical screening and antimicrobial activities of *Phyllanthus amarus* stem bark extracts. International Journal of Modern Biology and Medicines 3, 101-112.

Ward JW, Elsea JR (1997). Animal case and use in drug fate and metabolism, methods and techniques. Vol. 2. New York: Marcel Deker p. 431.

Wolking D (2013). Implementing a cold chain for safe sample transport and storage. http:www.vetmed.ucdavis.edu/ohi/predict/PREDICT_Publications.cfm#Protocols.