Methanol Root Extract of *Pausinystalia yohimbe*, an Aphrodisiac Influences Morphology of Sperm Cells in Male Wistar Rats

Adekunle Orimisan Ojatula*****

PhytoMedicine Division, Botany Unit, Department of Biological Sciences, School of Science, Olusegun Agagu University of Science and Technology, Okitipupa, Ondo State, Nigeria.
Submitted: 23rd February, 2022; Accepted: June 15, 2022; Published online: 30th June 2022
DOI: *https://doi.org10.54117/jcbr.v2i3.22*

*Corresponding Author: Ojatula, A. O. kunletula@yahoo,com; Tel. +2347054619103

Abstract

The production and classification of sperm shape abnormalities in laboratory animals through administration of chemical agents, be it natural or synthetic, has in recent years developed into a very reliable, species and drug specific method of assay for testing the mutagenicity of phytotherapeutic agent. In this research, observed numbers, percentage and types of dysmorphisms induced by the oral administration of *Pausinystalia yohimbe* methanol root extract in varying doses in male wistar rats were investigated. Forty five rats were randomly divided into five groups of nine rats each. Rats in group I (control) were administered 1 mL/kg distilled water, group II received 5 mg/kg body weight sildenafil citrate, while those in groups III, IV, and V were given 25, 50, and 100 mg/kg body weight of the extract respectively for 14 days after which they were sacrificed and sperm cells were analysed for possible morphological abnormalities. In this study, oral administration of the extract has significant ($p < 0.05$) effect on the morphology of sperm cells, with sperm normalities decreases, while abnormalities increases when compared with the control groups. However, the abnormalities decreased dose dependently with slightly increase in normalities. The abnormal morphology ranged from double heads, tailless sperm, headless sperm, double tails, short sperm and bent tail in both extract and sildenafil citrate administered animals. The tailless sperm morphological changes had the highest rate of occurrence. The observation confirmed that mutagenicity of chemical agents, be it natural or synthetic, could be tested and compared using the sperm head-shape abnormality assay method, thereby predicting simple to complex dysmorphisms.

Keywords: Fertility enhancer, Medicinal plant, Normalities, Sperm-shape, Testicular integrity

Introduction

Plants have been used as aphrodisiacs and for their spermatogenic properties because of the phytochemicals they contain. These phytochemicals/biomolecules are known to promote spermatogenesis, penile erection, vasodilatation, increase in testicular and/or serum cholesterol, and engorging of the penis for sexual performance. The effect can also be negative, either severe or not, on the sperm cell quality and it does, affect the morphology of the sperm cells and the kind of morphological changes that do occur (Ekere *et al*., 2013; Ojatula, 2017).

Abnormal forms of spermatozoa occurs in all mammals (Mann and Mann, 1981;

Saha and Bhattaacharya, 2016). It has been demonstrated that the fraction of dysmorphic forms of sperm could be experimentally augmented in laboratory through chemical, physical or mutagenic agents (Lu and Meistrich, 1979; Tophan, 1980; Saha and Bhattaacharya, 2016; Karmakar *et al*., 2018). In recent years, the application of fractional percentages of abnormal sperm types, which results from drug (synthetic or natural) assays has emerged as a reliable and specific variant in the analysis of mutagenicity of newer drug (Gilliman *et al*., 1985; Karmakar *et al*., 2018). In pioneering studies (Wyrobeck and Bruce, 1975), occurrence of dysmorphic spermatozoa and the typing and classification of abnormalities, caused by drug specificity of agents has been conclusively reported (Wyrobeck and Bruce, 1978). The constancy in the percentages of types of abnormality produced by specific drug, be it synthetic or natural, on murine sperm-shape has of late elevated this mode of study to satisfactory confidence level in drug assays (Gilliman *et al*., 1985). Although malformations are observed in many parts of the affected spermatozoon, the "head, neck and tail" shape dysmorphisms and its enumeration and classification have been accepted as the standard. The sperm head displays far less susceptibility to reaction to minor variations in experimental and preparation techniques (morphologically), than other parts of the spermatozoon (Mann and Mann, 1985; Karmakar *et al*., 2018).

Pausinystalia yohimbe is a common evergreen tree which belongs to the family of the Rubiaceae, this plant is known to be found amongst the south, west and central African region in the main forest and jungles of Cameroun, Nigeria, Gabon and equatorial-guinea (Dhir and Kulkarni, 2007). The plant, *P. yohimbe*, is known amongst the locals as "Idagbon (Yoruba), Likiba/Elikiba (Ibo/Edo), and Burantashi (Hausa)", it functions as a sexual enhancer to boost erection. Apart from its aphrodisiac properties, it is also used to treat exhaustions or energy booster, chest pain, skin disorders and inflammations (Duke, 1985).

Yohimbe is one of the few popular natural aphrodisiacs that is actually backed by science. It has been reported that *Yohimbe* extract in sufficient dose is an adrenoreceptor blocker that enhances erection (Saito *et al*., 1991). Animal studies also reported increases in libido and erectile functions in rats fed *yohimbe* root (Ojatula, 2017). Apart from being used as an aphrodisiac, it is commonly used in "suya' barbecued meat preparation (Ogwo, 2016). It has been linked with improved sperm cells quality amongst sexually active males in experimental animals (Al-Majed *et al*., 2006; Ojatula, 2017).

The sperm morphology assay is one of the most widely used genetic toxicology assays (Gilliman *et al*., 1985). Ability of the sperm to fertilize a functional ovum is considered as the ultimate criteria of its function (Shetty and Bairy, 2015). This study evaluated, for the first time, the effect of *Pausinystalia yohimbe* root on sperm morphology in male Wistar albino rats.

Materials and Methods

Experimental Animals

Sexually matured, healthy, male albino rats of Wistar strain (*Rattus norvegicus*), weighing about 230-300 g were obtained from the animal holding unit of the Department of Pharmacology and Toxicology, University of Benin, and

were used for the experiments. The animals were allowed to undergo acclimatization period of seven (7) days and were housed in a ventilated wooden cage. They were kept at room temperature 28 – 30ºC under natural light and dark cycle with free access to pelleted feed and tap water. Good hygiene was maintained by constant cleaning and removal of faeces from the cage on daily basis, with strict observation of Standard Operating Procedures (SOP) on handling of laboratory animals (Akah, 2009). All experiments performed on the laboratory animals in this study were approved by the Ethical Committee for animal experimentation in the Department of Pharmacology and Toxicology, Faculty of Pharmacy, University of Benin, Benin City, Nigeria.

Collection, Identification and Preparation of Plant Materials

Fresh roots of *Pausinystalia yohimbe* were obtained from Ugowan Village, near the boundary of Okomu National Park, Udo, Edo State, Nigeria during April to May 2015. The plant sample was identified and authenticated at the Herbarium of the Department of Plant Biology and Biotechnology of the University of Benin, Benin City, Edo State, Nigeria with the voucher number UPBHx1066. The fresh roots of *Pausinystalia yohimbe* collected were thoroughly washed and air dried inside the laboratory until constant weight was obtained. They were pulverized using an electric blender (RN4S, Mayer, China) and sieved to obtain the powdered form. One thousand two hundred grams (1,200 g) of the powdered form was extracted in 99% absolute methanol using Soxhlet apparatus. The extraction was carried out in cycles at a temperature of 50ºC, and each cycle lasted for 48 hours. Extract was evaporated to near dryness and as well, concentrated on a water bath under reduced pressure and low temperature. The slurry from methanol extract was later weighed and reconstituted in distilled water to give the required doses used in the study.

Experimental Design and Treatment

Methanol extract was prepared in Tween 80 (1%), suspended in 1 mL/kg distilled water and sildenafil citrate (0.05%) was also suspended in 1 mL/kg distilled water and administered orally using intragastric catheter. A total of 45 male rats, 5 months old (weighing 230 – 300g) were selected for study. They were randomly divided into five groups of nine rats each, and ear tags and colour codes were given to identify each animal. Group I animals served as the negative control and received 1 mL/kg distilled water. Animals in Group II received dose of sildenafil citrate (Viagra) 5 mg/kg orally daily for 14 days and served as positive control. Groups III, IV and V were administered with methanol extract of *Pausinystalia yohimbe* root on a daily dosage of 25, 50 and 100 mg/kg body weight respectively for 14 days.

Determination of Effects of the Extract on Sperm Morphology of Rats

The rats grouped and administered methanol extract of *P. yohimbe* root were used for the study. And at the end of the experimental period on day 14, the sperm cells were extracted by sacrificing the rats, locating the vas deferens which is ligated and cut, then placed on a petri dish, 3 drops of phosphate buffered saline was added, then it was teased to allow the sperm cells diffuse out easily, a drop of the sperm cells was taken and placed on a grease free clean slide, covered with a cover slip and viewed under the

microscope with the x40 objective lenses. The slide was air dried and later stained for 20 minutes with the improvised Leishmian and Eosin stain (Ibeh, 2018), and the slide was rinsed in distilled water and air dried then viewed with the x100 objective lenses for morphological abnormalities. The sperm morphologies were scored in percentage primarily as abnormal and normal, and later secondarily as the various observable abnormalities. Abnormal sperms are classified as, I: Head abnormality- that included: double heads, headless sperm, hookless, banana shaped and amorphous., II: Tail abnormality- which includes the coiled tail, tailless sperm, double tails and bent tail (Wyrobeck and Bruce, 1975).

Statistical Analysis

The data obtained were analysed by repeated measure analysis of variance (ANOVA) followed by Duncan's multiple range test for multiple comparisons using statistical package for social sciences (SPSS) software (Version 20) and Microsoft Excel (2013) software. The differences between means were considered significant at $p< 0.05$. Values were expressed as Mean ± Standard Error of the Mean (S.E.M.) and presented as figure.

Results

Effects of the Extract on Sperm Morphology of Rats

The results of both controls and test were tabulated and analysed. Oral administration of various concentrations of methanol extract of *P. yohimbe* root induced anomalies of the head and tail of sperms. The extract of the studied plant, has significant ($p < 0.05$) effect on the morphology of sperm cells, with sperm normalities decreases, while abnormalities increases when compared with the control groups (Figure 1). However, the incidence of abnormal sperms showed a dose dependent decrease in extract treated groups of rats, while normal sperm cells increased slightly in a dose dependent sequence, but still not as better than that of the control groups, even at the highest dose of 100 mg/kg (Figure 1). The standard drug (positive control) also exhibited slightly decrease in sperm normalities with slightly increase in sperm abnormalities compared to the negative control. In all the experimental groups of rats used for the study, the negative control has the highest incremental level of sperm normalities with the lowest decremental level of sperm abnormalities when compared with the extract and Sildenafil citrate (positive control) treatment groups of rats.

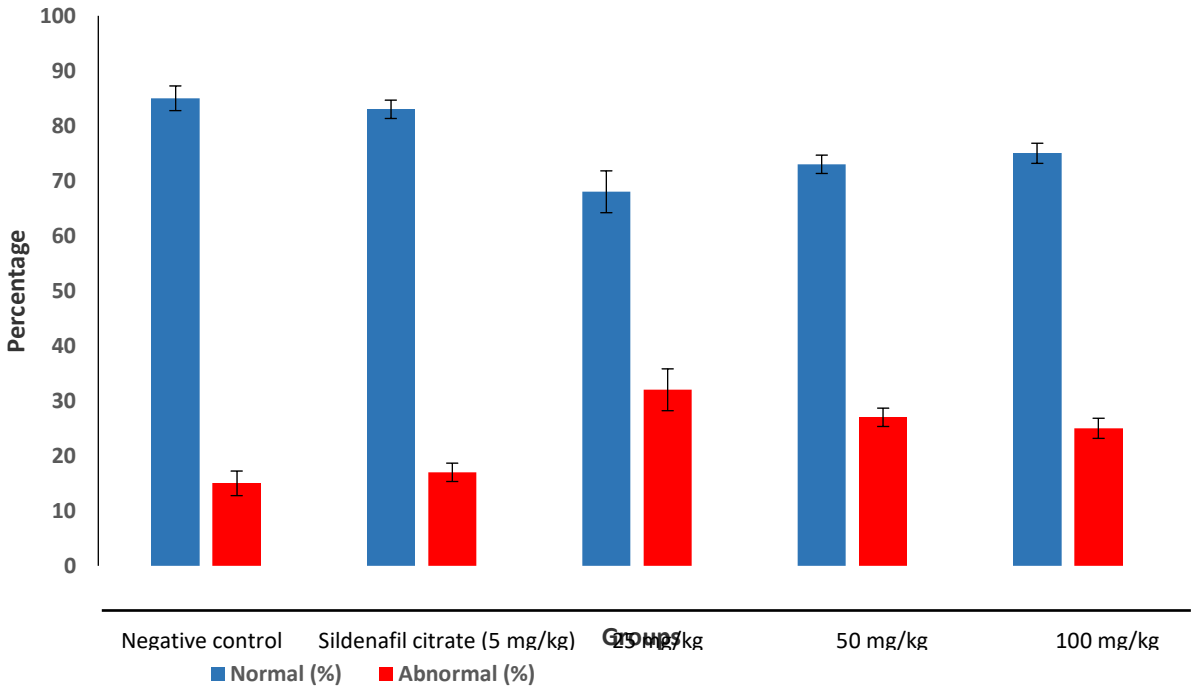

Figure 1: Effect of *Pausinystalia yohimbe* methanol root extract on morphology of sperm

Figure 2 replays the observable secondary abnormalities and their rate of occurrence in rat's sperm cells, with "tailless sperm" variant seen as the highest/dominant observable abnormality when compared across the treatment groups. The highest/dominant observable secondary abnormality (i.e., tailless sperm) was found occurring in groups of rats treated with 25 and 50 mg/kg body weight of the extract, and sildenafil citrate (Table 1).

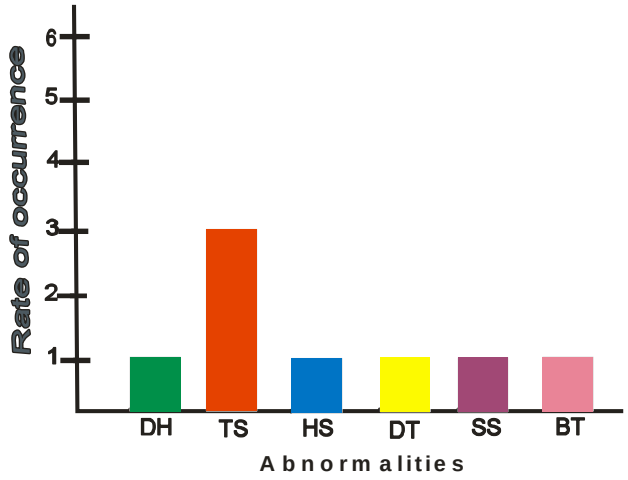

Figure 2: Rate of occurrence of abnormalities in sperm cells of treated rats*Where: DH = Double Heads; TS= Tailless Sperm; HS= Headless Sperm; DT= Double Tails; SS= Short Sperm; and BT = Bent Tail.

Table 1: Effect of *Pausinystalia yohimbe* methanol root extract on sperm morphology

Groups	Abnormalities
Negative control	Normal
Sildenafil citrate (5 mg/kg)	Double heads and tailless sperm
25 mg/kg	Tailless sperm and headless sperm
50 mg/kg	Double tails and tailless sperm
100 mg/kg	Short sperm and bent tail

Photomicrographic Evaluation of Sperm Cells of Experimental Rats

Prelude to Figures 4, 5, 6 and 7 when compared with the negative control (Figure 3), the various observable anatomical secondary abnormalities induced by the treatments at varying concentrations were double heads, tailless sperm, headless sperm, double tails, short sperm and bent tail respectively.

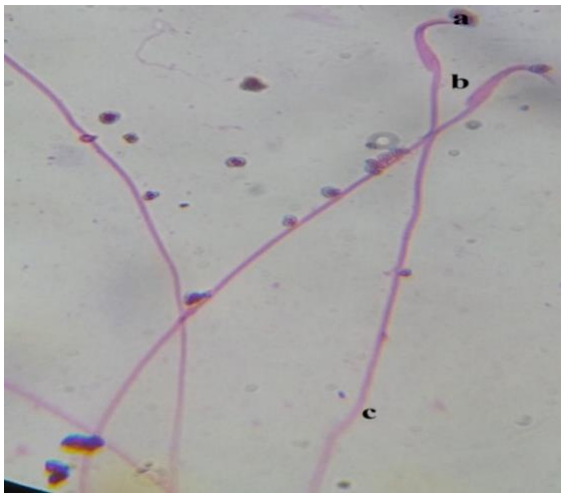

Figure 3: Photomicrograph showing negative control (distilled water) sperm cells: this shows normal sperm cells with head (a), neck (b), and tail (c)

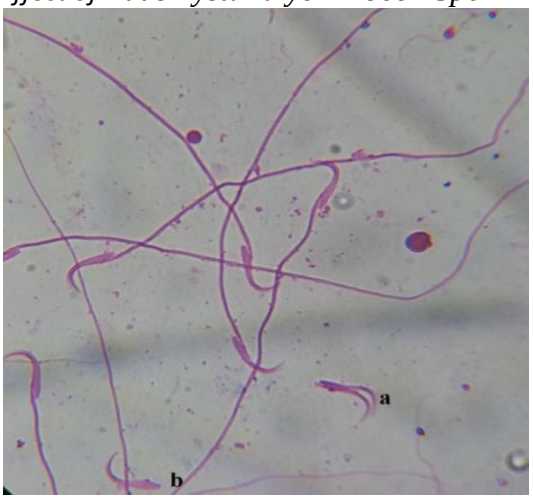

Figure 4:Photomicrograph showing abnormalities of sperm cells of rats treated with 5 mg/kg of Sildenafil citrate (Viagra): (a) double heads, (b) tailless sperm

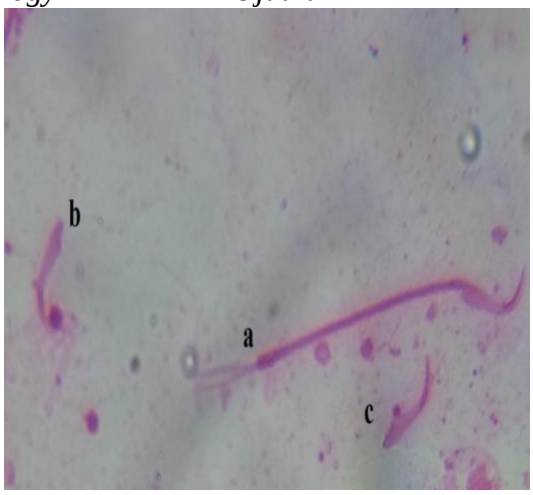

Figure 5. Photomicrograph showing abnormalities of sperm cells of rats treated with 50 mg/kg body weight of *Pausinystalia yohimbe* methanol root extract: (a) double tails, (b/c) tailless sperm

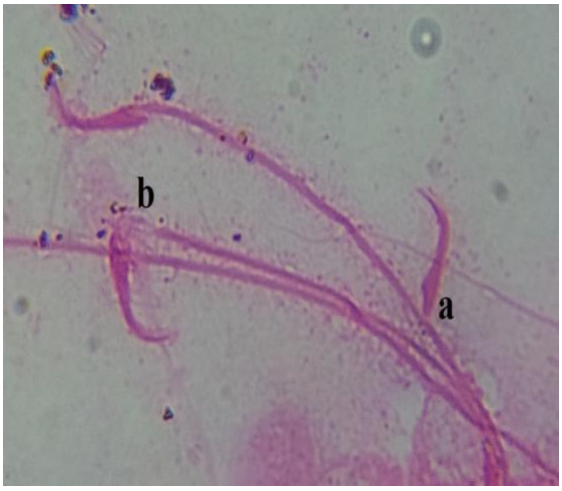

Figure 6: Photomicrograph showing abnormalities of sperm cells of rats treated with 25 mg/kg body weight of *Pausinystalia yohimbe* methanol root extract: (a) tailless sperm, (b) headless sperm



Figure 7. Photomicrograph showing abnormalities of sperm cells of rats treated with 100 mg/kg body weight of *Pausinystalia yohimbe* methanol root extract: (a) short sperm, (b) bent tail

Discussion

The biomechanisms that facilitate sperm production, motion and function are varied and complex (Mann and Mann, 1985). The reproductive capacity of sperm (count and viability) are important factors determining the outcome of *in vitro* fertilization and insemination procedures.

Sperm morphology is an important aspect in assessing sperm quality as well as a key index to evaluating reproductive toxicity and mutagenicity of exogenous chemicals. Spermatogenesis is a highly regulated differentiating system, both temporally and spatially. Germ cells, in particular, differentiating spermatozoa are extremely susceptible to cytotoxic agents because of their rapid proliferation. The non-proliferating Leydig cells and sertoli cells survive most cytotoxic therapies but could suffer functional damages (Shetty and Bairy, 2015). The sperm morphology assay is one of the most widely used genetic toxicology assay (Gilliman *et al.*, 1985). In reporting the evaluation of chemical genotoxicity, sperm head abnormality is the most reliable short term biological indicator (Wyrobeck, 1982). The sperm head morphology gives a rough assessment of the functional capability of the spermatozoa and reveal the quality of the sperm DNA. The structure of mature sperm consists of a head and a tail. The tail is divided into four distinct segments: the connecting piece adjacent to the head, the midpiece, and the principal end piece (Mann and Mann, 1985). In this study, *P. yohimbe* root extract was given orally for 14 days to estimate effect on the sperm morphology of experimental rats; and it was observed that extract of the studied plant, induced significant ($p < 0.05$) effect on the morphology of sperm cells, with sperm normalities decreases, while abnormalities increases when compared with the control groups (Figure 1). However, the incidence of abnormal sperms showed a dose dependent decrease in extract treated groups of rats, while normal sperm cells increased slightly in a dose dependent sequence, however, the observed morphology is still not better than that of the control groups, even at the highest dose (Figure 1). The standard drug (positive control) also exhibited slightly decrease in sperm normalities with slightly increase in sperm abnormalities compared to the negative control. In all the experimental groups of rats used for the study, the negative control performed better by having the highest incremental level of sperm mormalities with the lowest decremental level of sperm abnormalities when compared with the extract and Sildenafil citrate (positive control) treatment groups of rats. From the foregoing, it can be inferred that the extract has significant effect on the sperm morphology by having higher abnormalities with lesser mormalities. The abnormal morphology ranged from double heads, tailless sperm, headless sperm, double tails, short sperm and bent tail in both extract and sildenafil citrate administered animals. The tailless sperm morphological changes had the highest rate of occurrence. The observation confirmed that mutagenicity of chemical agents, be it natural or synthetic, could be tested and compared using the sperm head-shape abnormality assay method, thereby predicting simple to complex dysmorphisms.

It has been shown that *P. yohimbe* root enhances sexual performance and also exerts effect on the sperm cell quality as observed in this study (Table 1). The results from this study shows that *P. yohimbe* root has effect on the sperm cells since the percentage of sperm abnormalities are higher, with lesser sperm normality in their treatment groups compared to the negative control (Figure 1). As compared with previous work published by Ariagno (2002), *P. yohimbe* may not affect the sperm cell concentration and motility at a short exposure but reports have it that at a further exposure, it may cause mild damage to the morphology of the sperm cells; as observable in this study with a

steady decrease of the abnormality with the increase in the concentration of the plant material under study among extract treated groups of rats.

There are observable secondary variants of shape and size as compared with the control groups as also observed by previous study (Ogwo, 2016), with tailless sperm having the highest abnormality, this may be due to the pressure impacted by the local aphrodisiac and has led to distortion of the sperm cellular structure. Sperm abnormalities are the resultant end points after point mutations or other chromosome variations. It is possible that these changes in the sperm structure may be due to point mutation (Mann and Mann, 1985). In the results, sperm of the *P. yohimbe* treated groups and the sildenafil citrate showed tail and head abnormalities (Figures 4-7). However, the percentage of abnormal sperms observable in rats treated with all the doses of *P. yohimbe* root during the experimental period was higher than the percentage of normal sperms (Figure 1). Some sperm abnormalities were seen during the study period in the treated groups, which indicates that spermatocytes might have been susceptible to the toxic effect of *P. yohimbe*. The head abnormalities most probably reflect a change in DNA content (Wyrobeck and Bruce, 1978). Bending and coiling of sperm tail mainly involves its orientation, which gives an impression of a reduced sperm movement. Such limitation in sperm movement can reduce fertility in both animals and human. It has been reported that sperm comet assay and sperm head morphology are positively correlated (Shetty and Bairy, 2015). Comet assay measures DNA damage in the sperm, it can therefore be used to add further information on the quality of the sperm in the presence of *P. yohimbe*.

Sperm abnormalities are usually taken as characteristic criteria and as an applied test for monitoring the mutagenic potential for many chemicals. Increased level of abnormal sperms is an indication of mutagenic potency of the test chemical. The drug that induces abnormal sperms can be expected to clearly interfere with normal differentiation of germ cells (Wyrobeck, 1982).

Data generated clearly establishes that the extract produces a wide range of sperm shape abnormalities, depending on the dose of administration. In this study, sildenafil citrate was used as positive control, comparing with the result of negative control and the experimental groups. The resultant sperm morphological effects of all the doses of *P. yohimbe* root extract were also similar to that of sildenafil citrate effect.

Conclusion

Pausinystalia yohimbe root does affect the shape of the head and tail of the rat's sperm, and there lies a confirmatory observation that mutagenicity of chemical agents, be it natural or synthetic, could be tested and compared using the sperm head-shape abnormality assay method with a good degree of statistical confidence. From the foregoing, there were impacted effects on the morphology of spermatozoa in the short-time usage of this local aphrodisiac, and its long-time impact on the morphology may pose a threat of simple to complex abnormalities.

Acknowledgement

The author acknowledged the technical assistance of Dr. Gabriel Benjamen of the Department of Pharmacology and Therapeutics, Faculty of Pharmacy, University of Benin, Nigeria and Mr. S.

Ibeh of the University of Benin Health Centre.

Conflict of Interest

The author declare no conflict of interest.

References

Akah JA (2009). Effects of *Vernonia amygdalina* on biochemical and haematological parameters in diabetic rats. *Asian Journal of Medical Sciences*, 1(3): 108-113.

Al-Majed AA, Al-Yahya AA, Al-Bekairi AM, Al-Shabanah OA, Qureshi S (2006). Reproductive, cytological and biochemical toxicity of Yohimbe in male swiss albino mice. *Asian Journal of Andrology*, 8(4): 469-476.

Ariagno J (2002). Shedding of immature germ cells. *Archives of Andrology*, 48: 127-131.

Dhir A, Kulkarni SK (2007). Effect of addition of yohimbine (alpha-2-receptor antagonist) to the antidepressant activity of fluoxetine venlafaxine in the mouse forced swim test. *Pharmacology*, 80(4): 239-243.

Duke J (1985). CRC handbook of medicinal herbs, Boca-Raton, FL, CRC Press: 351p.

Ekere SO, Okoye CN, Udoumoh AF (2013). Fertility enhancing effects of methanolic leaf extract of *Dracaena arborea* in albino rats. *Czech Journal of Animal Sciences*, 58(11): 520-524.

Gilliman AG, Goodman LS, Rall TW, Murad F (1985). The pharmacological basis of therapeutics, 7th edition, New York, Macmillan Press: 132-145.

Ibeh NI (2018). Improvised Eosin and Leishman as morphological stain for sperm cell analysis in adult male wistar rats and rabbits as a model of study. *Acta Scientific Microbiology*, 1(1): 10-20.

Karmakar PC, Cho Y, Kim Y, Jung S, Jim J, Kim B, *et al* (2018). Chemotherapeutic drugs alter functional properties and proteome of mouse testicular germ cells *in vitro*. *Toxicological Sciences*, 164(2): 465-476.

Lu CC, Meistrich ML (1979). Cytotoxic effects of chemotherapeutic drugs on mouse testes cells. *Cancer Research*, 39: 3575-3582.

Mann T, Mann CL (1981). Male reproductive function and semen. Springer-Verlag, Berlin: 73-74.

Mann T, Mann CL (1985). Male reproductive function and semen, 2nd revised edition, Berlin, Springer-Verlag: 103-114.

Ogwo EU (2016). Semen quality in male albino rats fed with various concentrations of *Pausinystalia yohimbe* bark powder (Burantashi). *Journal of Medical and Dental Science Research*, 3: 16-24.

Ojatula AO (2017). Bioactivity and safety assessment of *Pausinystalia yohimbe* (K. Schum.) Pierre ex Beille root extract on male sexual and spermatic parameters in wistar rats. Unpublished PhD Dessertation, PhytoMedicine. University of Benin, Faculty of Life Sciences, Benin City, Nigeria, 266p.

Saha P, Bhattacharya S (2016). Induction of sperm-head abnormality in Swiss albino mice (*Mus musculus*) by administration of fresh and processed

betel nut extracts. *Current Sciences*, 110(5): 891-896.

Saito TR, Hokao R, Aoki S, Chiba N, Teradas M, Saito M (1991). Central effects of yohimbine on copulatory behaviour in aged male rats. *Jikken Dobutsu*, 40(3): 337-341.

Shetty SD, Bairy KL (2015). Sorafenib induced sperm shape abnormalities in male swiss albino mice. *Research Journal of Pharmaceutical, Biological and Chemical Sciences*, 6(3): 950-955.

Tophan JC (1980). The detection of carcinogen induced sperm head abnormalities in mice. *Mutation Research*, 1: 149-155.

Wyrobeck AJ, Bruce WR (1975). Chemical introduction to sperm abnormalities in mice. *Proceedings of the National Academy of Sciences*, 72(2): 4425-3529.

Wyrobeck AJ, Bruce WR (1978). The introduction of sperm shape abnormalities in mice and human. *Chemical Mutagens*, 5: 257-283.

Wyrobeck AJ (1982). Sperm assays as indicators of chemically induced germ cell damage in man, in: Heddle A. J. (ed.), mutagenicity, new horizons in genetic toxicology. New York, Academic Press: 337-34.