Scrotal primary sclerosing lipogranuloma in a young nigerian male. A case report with a review of literature.

[1]Godwin D Yovwin[1], Jude O Uchendu[2]*, Christopher O Idemudia[3]

[1]Department of Family Medicine, Delta state University Teaching Hospital, Oghara, Nigeria

[2]Department of Histopathology and Morbid Anatomy, Delta state University, Abraka, Nigeria

[3]Safe Haven Medical Centre, Benin City, Nigeria.

Submitted: 13th June, 2022; Accepted: 19th June, 2022; Published online: 30th June 2022

DOI: *https://doi.org10.54117/jcbr.v2i3.17*

Corresponding author. Dr Jude Obiora Uchendu +2348038732062 ojlinksent@yahoo.com

ABSTRACT

Sclerosing lipogranuloma (SL) of the male external genitalia is a rare chronic inflammatory lesion presenting as subcutaneous masses. The underlying pathological process is a chronic granulomatous reaction of degenerating endogenous or exogenous lipids. We report a case of primary scrotal SL in a 22-year-old Nigerian. The lesion was completely excision and the patient is on long-term follow-up without recurrence.

Keyword: Scrotal mass Lipogranuloma, Excision

INTRODUCTION

Sclerosing lipogranuloma SL is a rare chronic granulomatous inflammatory lesion that manifests as subcutaneous swelling of the male external genitalia. This lesion has also been reported occasionally in other organs. Its etiology is commonly related to an inflammatory response to injected exogenous lipid, although primary SL has also been less often documented. (Smetana and Bernhard, 1950). Here we present the first case of idiopathic scrotal primary SL in a 22-year-old Nigerian male.

CASE REPORT

A 22-year-old man presented with a slowly growing, painless right scrotal mass of four years duration. There is no history of previous trauma or injection of exogenous material into the scrotum. Physical examination revealed a right scrotal mass of about 6cm diameter, which is attached to the overlying skin. There is no associated skin ulceration or lymphadenopathy. The left testicle is apparently not affected. A clinical assessment of para-testicular tumour was made.

Laboratory investigations such as full blood count, blood chemistry and alpha fetoprotein were within normal limits. Ultrasound

examination showed a large scrotal cystic mass, with extension into the right inguinal region, and distinctly separate from the right testes. The left testicle is of normal size, shape and consistency.

Patient was booked for excision biopsy. At surgery, there was a right scrotal mass, which was mildly attached to the scrotal skin. The mass was in the para-testicular region and was ovoid in shape. The mass was completely excised under local anesthesia and the skin reconstructed. The specimen was preserved in 10% formal saline solution and submitted for histological evaluation.

Gross examination revealed an encapsulated, cystic mass of 5 cm diameter with a central yellow, necrotic area. This is shown in Figure 1.



Figure 1. Excised specimen of Primary Sclerosing Lipogranuloma of 5 cm diameter. Specimen was opened up after surgery.

The wall is irregular with a wall thickness of 1-2 cm and variable central cavity. Histological examination reveals a chronic granulomatous inflammatory lesion with numerous areas of fat necrosis, cholesterol clefts, lymphocytic and histiocytic infiltrates and numerous foreign-body type giant cells in the cyst wall. This is shown in figure 2 and 3.

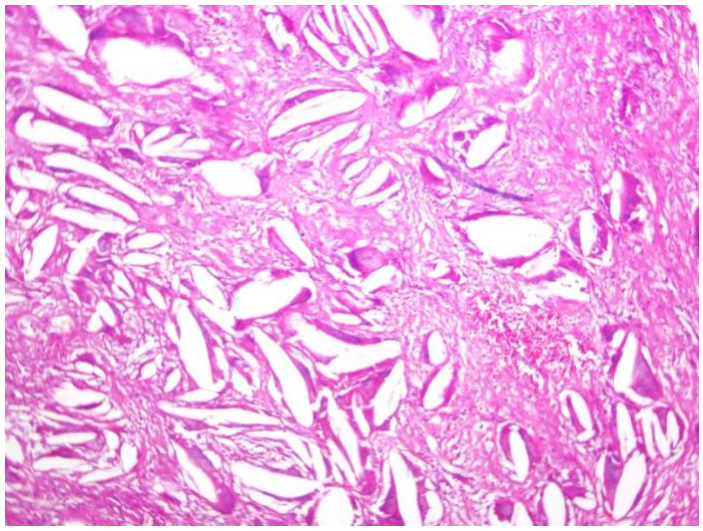

Figure 2. Histological section of the wall of the cyst showing multiple cleft spaces, a sclerotic background, sparse lymphocytic infiltrates and multiple multinucleated giant cells.(X10 magnification)

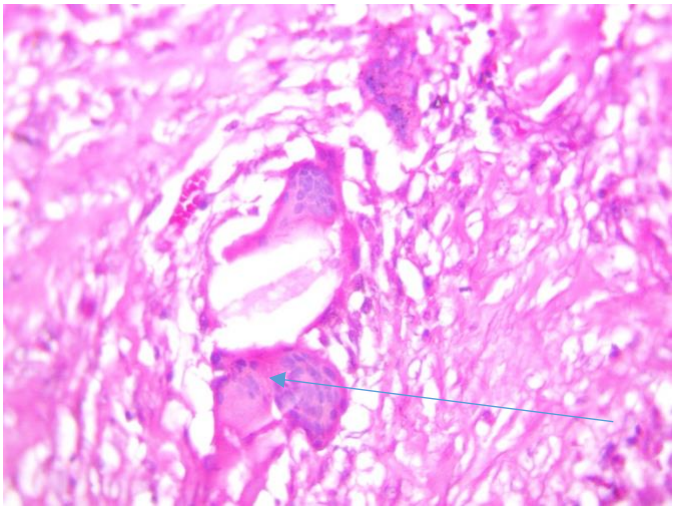

Figure 3. At higher magnification to highlight foreign body type multinucleated giant cells (arrow)

A final diagnosis of primary SL of the right scrotum was made. Patient is being followed up after a post-operative antibiotic coverage. He is currently doing well and there is no sign of recurrence several months after.

DISCUSSION

The name LS was introduced into medical literature by Smetana and Bernhard in 1950, to depict the sclerosis and granulomatous inflammatory response incited after injection of exogenous lipid into the male external genitalia in affected patients. (Smetana and Bernhard, 1950). The disease usually affects young males and appears to be relatively more common in some parts of the globe, especially in Japan and is often related to injection of exogenous substances into the genitalia to enhance its appearance. These cases have been documented in the penis, scrotum, spermatic cord and perineum. (Mungani *et al*., 2014; Oertel and Johnson 1977). In the index case, the lesion was limited to the right scrotum and the patient however denied any history of injection of exogenous substance to the genitalia.

Three possible initiating pathways to the disease have been proposed by some authors.

a) Those arising from injection of exogenous substances such as silicon, paraffin oil, mineral oil, vaseline etc into the external genitalia. (Oertel and Johnson *et al*., 1977). This is referred to as Secondary SL
b) Those resulting from the reaction of the body to endogenous lipids, aggravated by heat, cold, infection or trauma, or vigorous sexual intercourse. (Singam *et al*., 2010). This is referred to as primary SL
c) An allergic mechanism, usually characterized my dense eosinophilic infiltrates in the tissue and peripheral eosinophilia. This is described as eosinophilic SL. (Matsuda et al., 1988).

It is however generally accepted that the disease progression is perpetuated by chronic inflammatory response, mostly in response to persistence endogenous or exogenous degenerating lipid molecules. (Matsuda *et al*., 1988; Oertel and Johnson, 1977; Singam *et al*., 2010).

The usual clinical presentation of scrotal SL is a painless to slightly tender, slow growing subcutaneous mass. (Kara *et al*., 2004). Our patient had a painless growth for a period of four years. Neoplastic disorders, tuberculosis, fungal infection, and foreign body granuloma are important differential diagnoses. In the index case, the laboratory investigations ruled out the possibility of these considerations.

The histological features are pathognomonic and consist of hyalinized stroma, sclerosis, and infiltrates of lymphocytes, macrophages, and multinucleated giant cells. Calcification has also been described in long-standing lesions. (Sahin *et al.,* 1991. In this case, eosinophils and calcification are absent.

Interestingly, its management is independent of the etiology. It is divided into conservative and surgical treatment. The surgical approach involves complete or partial removal of the lesion with or without a reconstructive skin flap. The Conservative approach fluctuates from close monitoring, symptomatic treatment, antibiotics to oral corticosteroid administration. Some authors have documented good response to oral corticosteroids given over a 6-week period. (Singam *et al*., 2010). Steroids have also proven efficacious in the treatment of eosinophilia seen in primary SL. Nathan *et al*., 2006. Our patient had complete excision

of the lesion and has been on follow-up for several months without recurrence.

In conclusion, we describe the first case of primary scrotal SL in a Nigerian male, who has been successfully treated by complete surgical removal of the lesion.

ACKNOWLEDGEMENT

The authors are greatly indebted to the management of Apex Pathology Center and Safe Haven Medical Centers for their support.

REFERENCE

Kara IG, Bayramoglu H, Ocse H (2004): Sclerosing lipogranuloma of male genitalia. European Journal of Plastic Surgery. 27(5), 249-252.

Matsuda T, Shichiri Y, Hida S, Okada Y, Takeuchi H, Nakashima Y, et al. (1988): Eosinophilic sclerosing lipogranuloma of the male genitalia not caused by exogenous lipids. J Urol. 140, 1021–1024.

Mungani S, Karaguzel E, Turan C, Reisi A (2014): A Giant Primary Sclerosing Lipogranuloma of the Scrotum. Turk Patoloji Derg. 30, 78-80.

Nathan L, David A, Damien MB (2006): Sclerosing lipogranuloma of the genitalia treated with corticosteroids. Int Urol Neph. 38, 97–99.

Oertel YC, Johnson FB (1977): Sclerosing lipogranuloma of male genitalia. Review of 23 cases. Arch Pathol Lab Med. 101(6), 321-326.

Sahin A, Tekgül S, Ergen A, Basar I, Dilek H, Ruacan S (1991): Sclerosing lipogranuloma
of the penis: a case report. Int Urol Nephrol. 23, 595-598.

Singam P, Suriyani L, Ho C, Hong GE, Zainuddin Z (2010). Primary sclerosing lipogranuloma: an unusual scrotal mass. Libyan J Med. 5, 5524.

Smetana HF, Bernhard W (1950): Sclerosing lipogranuloma. Arch Pathol. 50, 296-325.