Ultrasonographic Evaluation of Antihypertrophic Scar Activity of Successive Extract of *Musa cavendishii* Peel in New Zealand Rabbit Ear Scar Model

Azeez Raji Sheidu[1]*, Bello Bilkisu Maiha[2], Mohammed Garba Magaji[2], Ahmed Abubakar[3], Abdurrahman Mohammed[4], Lawal Maruf[4]

[1]FCT Schools of Nursing and Midwifery, Gwagwalada, Abuja, Nigeria
[2]Department of Pharmacology and Therapeutics, Ahmadu Bello University, Zaria, Nigeria
[3]Department of Pharmacognosy and Drug Development, Ahmadu Bello University, Zaria, Nigeria
[4]Department of Veterinary Surgery and Radiology, Ahmadu Bello University, Zaria, Nigeria

Submitted: Jan, 2022; Accepted: March 10, 2022; Published online: April 30, 2022
https://doi.org/10.54117/jcbr.v2i2.15

***Corresponding author:** Azeez Raji Sheidu, Loneumajene4real@yahoo.com
+2348035927240, +2348186905326

Abstract

Hypertrophic scar is a slow growth spherical shape with progressive expansion and absent skin infiltration which has high recurrence rate after injury to the deep dermis. Evaluation of this scar in New Zealand rabbit ear after administration of different doses of *Musa cavendeshii* peel extracts provide an informative data in monitoring the changes in scar indices.The objectives of this research was to evaluate the antihypertrophic scar activity of *Musa cavendishii* peel extracts using ultrasonography. LD_{50} of the extracts was conducted using OECD 402, (2017) guideline for chemical testing. Scar was created in the rabbit ear by full thickness excision wound under general anesthesia and sterile condition. The ultrasound monitoring was divided into 2 parts to evaluate the scar regression for 30 days in the different doses of the extracts. The dermal median lethal doses (LD_{50}) of all the extracts were estimated to be greater than 5000 mg/kg in rabbits. The results revealed a significant ($p \leq 0.05$) decrease in the scar indices evaluated during the 30 days where 2000 and 5000 mg/kg body weight of aqueous extract was used. However, the 30 days monitoring of the scar using 375, 750 and 1500 mg/kg of all the extracts when compared with the standard drug did not produce any significant ($p \geq 0.05$) changes on the scars. Peel extracts of *M. cavendishii* showed antihypertrophic scar activity which was effectively monitored using ultrasonography

Keywords: Antihypertrophic scar, Ultrasonography, *Musa cavendeshii* peel, Rabbit ear

Introduction

Hypertrophic scar and keloid are the most annoying and irritating outcomes of cutaneous development in the skin during wound healing processes (Lee and Jang, 2018). They are skin abnormalities peculiar to humans that are characterized by excessive deposition of extracellular matrix components like collagen, fibronectins, elastin, proteoglycans and growth factors in the dermis and subcutaneous tissues as a result of trauma or surgical interventions which can have devastating consequences ranging from body disfigurement to organ dysfunctions (Tracy *et al*., 2016).

The use of herbal medicine as a remedy has been steadily increasing worldwide in recent years, as well as the search for new

phytochemicals that could be potentially developed as useful drugs for the treatment of hypertrophic scar and skin lesions (Adebayo and Krettli, 2011). The antihypertrophic scar activity of these medicinal plants results from a variety of components and their phytochemical constituents. One of these medicinal plants is *glycine max* also called soya bean which is an annual legume of the pea family (Fabaceae). This plant has genistein as one of its components with effects as an anti-proliferation of hypertrophic scar fibroblasts, suppression of mitosis and promotion of apoptosis *in vitro*. The mechanism of action is the inhibitory trans-differentiation of fibroblasts into myofibroblasts, a decrease of G_0-G_1 phase and increase of G_2-M phase. It is also found to have inhibitory mRNA expression of C-JUN and C-FOS mRNA expression at 37 µM, but enhancement at 370 µM (Cao *et al*., 2009; Jurzak and Adamczyk, 2013).

Musa cavendishii is a fruit of a banana cultivar belonging to the cavendishii subgroup of the AAA (triploid) cultivar group. They include commercially important cultivars like the "Dwarf cavendishii and Grand Nain". The peel from these plants is used in many communities in "Ebira land" in the management of wound, burns, ulcers and scars. It is called "*apara ogede*" in Ebira land, "*bayan ayaba*" in Hausa, "*epo ogede*" in Yoruba, "*lare ayaba*" in Fulfunde and "*azu uli*" in Igbo language. The phytochemical constituent that is involved in its use for the management of this wound complication had been established in our previous work (Sheidu *et al*., 2021). Drug development for ameliorating a disease involves both preclinical and clinical processes that require critical monitoring through different scientific means. Ultrasonography and Vancouver scar scale indices are objective and non-invasive tools for evaluation of dynamic hypertrophic scar of the skin. The use of Doppler and high-resolution sonography to evaluate hypertrophic scar has been reported to be useful in pharmacotherapies (Ruiqian *et al*., 2020). The present study was to evaluate the antihypertrophic scar activity of *M. cavendishii* peel using ultrasound scan and Vancouver scar scale (VSS) techniques.

Materials

Animal

Fifteen (15) apparently healthy New Zealand rabbits of both sexes weighing between 1.2 to 2.2 kg were gotten from National Animal Production Research Institution (NAPRI), Shika-Zaria, Kaduna and housed in the Rabbit Section, Animal House Facility of Department of Pharmacology and Therapeutics, Ahmadu Bello University, Zaria. The animals were maintained under ambient environmental conditions and fed with standard rodents pellet diet and water *ad libitum*. The experiments were approved by the Ahmadu Bello University Committee on Animal Use and Care with approval number of ABUCAUC/2018/075 and all the experiment were carried out in accordance with the criteria outlined in the guide for the care and use of laboratory animals by the National Institutes of Health (Publication No 80-23, revised, 1996).

Drugs and Chemicals:
The following drugs and chemicals were obtained and used for the experimental studies
Ketamine hydrochloride injection USP (Jawa International limited, Nigeria), Ultrasound scan gel (Sonosonic Global Enterprise, Zaria), Atropine sulphate (American Remedies Healthcare Pvt. Ltd.), Xylazine (Akorn, Inc.), Methylated spirit B.P (Ugolab productions, Nigeria Limited), Germ-x hand sanitizer, Purit antiseptic (Saro Life Care Limited, Nigeria)

Equipment
The following equipment were obtained and used for the experimental studies:
A high-resolution laptop ultrasound scanner fitted with a 20 MHz transducer

Methods

Plant collection and identification:
The *Musa cavendishii* plant comprising the bulb, leaves and stalk was collected from Obehira, Okene Local Government, Kogi state, Nigeria after identification following a series of enquiries and interactions with the traditional healers in the community about the use of the plant. The whole plant was then taken to the Herbarium Section of the department of Botany, Ahmadu Bello University, Zaria, authentication by Mallam Namadi Sunusi. The sample was authenticated by comparing with an existing specimen (voucher specimen number, VSN: 28003).

Extraction:
The butch of the *Musa cavendishii* was separated and placed inside a closed sac for natural ripening to take place for 3 days. After ripening, the *Musa cavendishii* was distributed to volunteers for consumption after which the peels were collected. The peels were air-dried in a dark until constant weight was obtained. The dried peels were size-reduced into coarse powder using pestle and mortar. Successive extraction process was employed by maceration using the method of Abubakar *et al*. (2019), modified by Sheidu *et al*., (2021).

Hypertrophic scarring in rabbit ear:
The method developed by Morris *et al.*, (1997) and validated by Rittie and Laure, (2017) was used with modifications. A used X-ray film was used as a mimic to replace a rabbit dermal jacket (Plate I) which was placed on the ventral region of the rabbit's ear. This was followed by marking 6 mm in diameter in two places in the used x-yay film where the scar was intended to be created (Plate II). A total of fifteen (15) rabbits divided into five groups were used for this study. Each group had three (3) rabbits. Inter-observer variability test was carried out by a consultant wild life veterinary specialist on the scar created every week till the fourth week before the commencement of *M. cavendishii* peel extract administration. Before the start of the excision in the skin of the rabbits, each of the rabbit was secured gently and anaesthetized with xylazine, 3 mg/kg of body weight and ketamine, 50 mg/kg of body weight. A full-thickness excision wound was made to the cartilaginous surface over the ventral side of the rabbit marked with blue pen.
Haemostasis was achieved by gentle application of digital pressure with gauze on the side of the wound created. In phase one study, 2000 mg/kg and 5000 mg/kg body weight of aqueous extract of *M. cavendishii* peel was administered for 30 days just for the purpose of measuring the scar with ultrasound scan comparing the result with Vancouver scar scale parameters as visualized and measured using thread where applicable. The second phase study was after the LD_{50} of the extracts had been

determined and chosen doses of 375 mg/kg, 750 mg/kg and 1500 mg/kg per body weight were used. All the rabbits in the group were assigned each dose to the area of the scar that was formed after the fourth (4th) weeks of excision and the other area of the scar in the same rabbit was assigned a distilled water to serve as negative control during the acute toxicity study for ultrasound monitoring (phase one). Also the second phase of the study during the sub-acute toxicity were assigned the dose of 375, 750 and 1500 mg/kg body weight of *M. cavendishii* peel extracts and the other scar in the same rabbit was administered a standard drug, triamcinolone acetonide, all secured with a gauze and plaster in order to compare the effectiveness of the extracts and the triamcinolone acetonide.

A high-frequency laptop ultrasound scanner (Sonostar, China) was used to produce images of cross-sections of the scar centered on the transverse axis of each lesion. The scanner operates at a frequency of 20 MHz and scans rapidly and continuously, with axial resolution of 50 mm and a lateral resolution of 300 mm; giving an image with high definition, suitable for studying scar reduction or growth. An aqueous transmission gel (Sonosonic Global Enterprise, Zaria) was used to provide acoustic contact between the scar and transducer surface. At every week interval, the ultrasound scanner was used to visualize the depth, distance and area of the scar after cleaning off the administered plant extracts and that of the standard drug, triamcinolone acetonide (TCA) with gauze soaked in methylated spirit especially in sub-acute phase where TCA was used. Ultrasound gel was now applied on top of the scar to be measured and an area of hyper-echogenic region is measured in depth, distance and area using linear probe transducer. This was repeated for every week for consecutive four (4) weeks and measurement was done every week and recorded. All the measurements were obtained by the lead researcher. Satisfactory results of intra-observer and inter-observer variability between the researcher and diagnostic imaging consultant were obtained before the measurements were made. Vancouver scar scale (VSS) was also used to compare the scar parameter with that of the ultrasound especially the diameter in length where thread was used and later placed on ruler to take the accurate distance.

Statistical Analysis

Statistical package for Social Sciences (SPSS, Version 23) was used for data analysis. Differences between means was analyzed using one-way ANOVA and repeated measurements of ANOVA was also done to compare the differences of data between and within groups followed by Bonferroni's post hoc test to determine the level of statistical significance. Values of $p \leq 0.05$ were considered statistically significant and the results were presented as Mean ± S.E.M. in tables

Results

Effect of Administration of Aqueous Extract of *Musa cavendishii* Peel on Evaluation of Rabbit's ear Scar Using Ultrasound Scan in First Phase Study

The result of 30 days monitoring of rabbit ear's scar after dermal administration of *M. cavendishii* peel extract at doses 2000 mg/kg and 5000 mg/kg revealed that there was significant ($p \leq 0.05$) decrease in the diameter and the length of scar lesion at week 1, 2, 3 and 4 respectively when compared with the distilled water group. Also using area as a parameter of measurement, the sonographic assessment produced a significant ($p \leq 0.05$)

decrease at week 1 and 2 at dose 5000 mg/kg and in week 3 and 4, there was significant ($p \leq 0.05$) decrease at dose 2000 and 5000 mg/kg respectively. However, there was no significant ($p \geq 0.05$) change at week 1 at dose 2000 mg/kg (Table 1).

Effect of Administration of Successive Extracts of *M. cavendishii* Peel on Weekly Evaluation of Rabbit Ear Scar Using Ultrasound Scan in Second Phase Study

The result of 30 days monitoring of the scar in the ear of rabbits after application of other doses like 375, 750 and 1500 mg/kg respectively of *M. cavendishii* peel extracts did not produce a significant ($p \leq 0.05$) changes on the scars when compared with the standard drug, triamcinolone acetonide (Table 2).

Effects of Administration of Successive Extracts of *M. cavendishii* Peel on Weekly Evaluation of Rabbit Ear Scar Using Vancouver Scar Scale

The Vancouver scar scale showed hyperpigmentation at week 1 which decreased to normal at week's interval. The vascularity of the scar skin showed pink through-out the study and the pliability is all film with weekly visualization. The height measured with thread at week 1 is between 1 to 2 mm which decreased at week interval as compared to values in Table 3

Table 1: Effect of Administration of Aqueous Extracts of *Musa cavendishii* Peel on Evaluation of Rabbit's ear Scar Using Ultrasound Scan at Doses 2000 and 5000 mg/kg

Treatment (mg/kg)		Scar indices		
		Diameter (mm)	Length (mm)	Area (cm^2)
D/W		11.20 ± 0.00	15.30 ± 0.00	0.96 ± 0.00
Week 1	2000	10.47 ± 0.23	13.82 ± 0.46	0.88 ± 0.02
	5000	09.48 ± 0.20[a]	12.30 ± 0.20[a]	0.79 ± 0.03[a]
Week 2	2000	09.45 ± 0.33[a]	13.15 ± 0.40[a]	0.81 ± 0.03[a]
	5000	08.30 ± 0.20[a]	11.10 ± 0.20[a]	0.72 ± 0.03[a]
Week 3	2000	08.13 ± 0.35[a]	10.23 ± 0.62[a]	0.66 ± 0.04[a]
	5000	07.48 ± 0.21[a]	08.90 ± 0.13[a]	0.63 ± 0.02[a]
Week 4	2000	07.43 ± 0.40[a]	09.02 ± 0.34[a]	0.54 ± 0.03[a]
	5000	05.52 ± 0.23[a]	06.77 ± 0.22[a]	0.53 ± 0.02[a]

Values are expressed as Mean ± S.E.M., Data were analyzed using One way ANOVA and Repeated measurements of ANOVA followed by Bonferroni's post hoc test, [a] = $p \leq 0.05$ as compared with the Distilled water, n=3.

Table 2: Effect of Administration of Successive Extracts of *Musa cavendishii* Peel on Weekly Evaluation of Rabbit Ear Scar Using Ultrasound Scan at Doses 375 mg/kg, 750 mg/kg and 1500 mg/kg

	Scar Indices-Treatment (mg/kg)			
	Week 1	Week 2	Week 3	Week 4
TCA, 40	11.50 ± 0.50	11.35 ± 0.45	11.15 ± 0.45	10.65 ± 0.45
HEMC 375	11.10 ± 0.10	10.90 ± 0.10	10.65 ± 0.15	10.25 ± 0.15
HEMC 750	10.85 ± 0.05	10.65 ± 0.05	10.45 ± 0.05	10.10 ± 0.10
HEMC 1500	10.90 ± 0.00	10.75 ± 0.05	10.55 ± 0.05	10.15 ± 0.05
EEMC 375	10.85 ± 0.05	10.70 ± 0.10	10.55 ± 0.05	10.15 ± 0.05
EEMC 750	11.35 ± 0.45	11.05 ± 0.45	10.90 ± 0.50	10.10 ± 0.00
EEMC 1500	12.15 ± 0.25	11.95 ± 0.25	11.75 ± 0.25	11.55 ± 0.25
MEMC 375	10.85 ± 0.05	10.65 ± 0.05	10.45 ± 0.05	10.10 ± 0.00
MEMC 750	10.85 ± 0.05	10.65 ± 0.05	10.50 ± 0.00	10.15 ± 0.05
MEMC 1500	10.80 ± 0.10	10.65 ± 0.05	10.50 ± 0.00	10.15 ± 0.05
AEMC 375	11.95 ± 0.05	11.75 ± 0.05	11.05 ± 0.45	10.65 ± 0.45
AEMC 750	11.80 ± 0.10	11.60 ± 0.10	11.40 ± 0.10	11.05 ± 0.05
AEMC 1500	11.85 ± 0.05	11.55 ± 0.05	11.35 ± 0.05	11.05 ± 0.05

Values are expressed as Mean ± S.E.M. Data were analyzed using Repeated measured ANOVA followed by Bonferroni's post hoc test, $p \geq 0.05$, n=3.
Key: TCA = Triamcinolone acetonide, HEMC = Hexane extract of *M. cavendishii*, EEMC = Ethylacetate extract of *M. cavendishii*, MEMC = Methanol extract of *M. cavendishii*, AEMC = Aqueous extract of *M. cavendishii*

Table 3: Vancouver Scar Scale in Comparing with Ultrasonography Results

Pigmentation (0-2)	Normal	0
	Hypopigmentation	1
	Hyperpigmentation	2
Vascularity (0-3)	Normal	0
	Pink	1
	Red	2
	Purple	3
Pliability (0-5)	Normal	0
	Supple	1
	Yielding	2
	Firm	3
	Banding	4
	Contracture	5
Height (0-3)	Normal (flat)	0
	0-2 mm	1
	2-5 mm	2
	>5 mm	3

Adapted from Thompson *et al.*, 2015

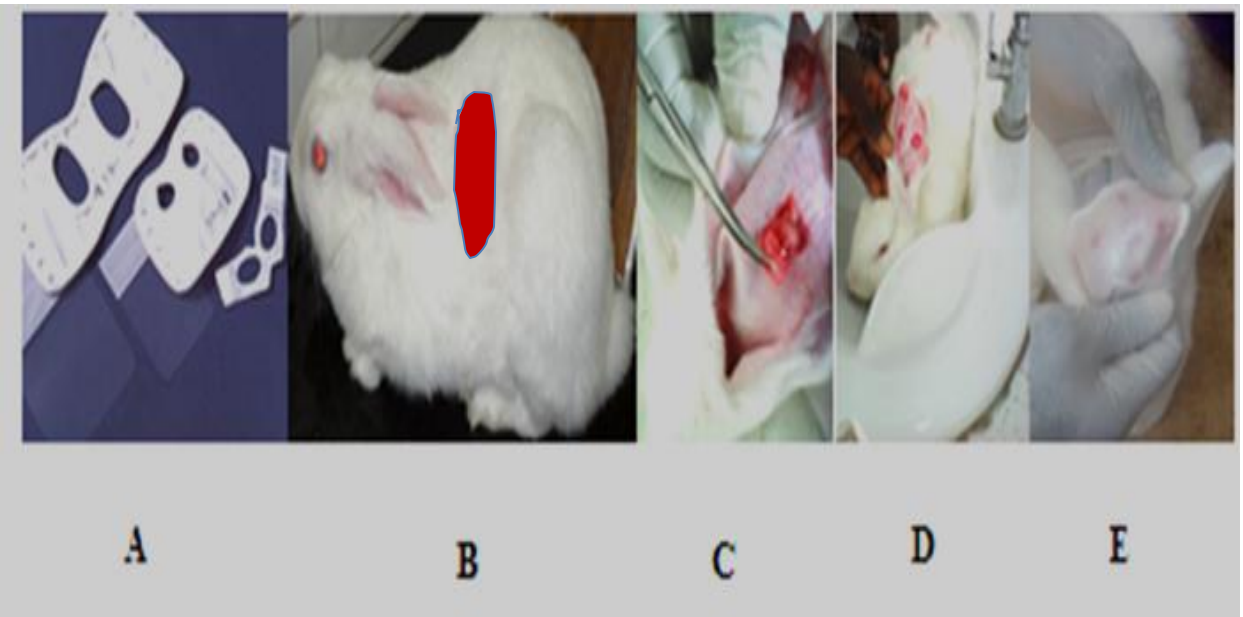

Plate I: Method of Dermal Toxicity Study and Antihypertrophic Scar

A = Rabbit Dermal Jacket, B = Dermal Area for Application of Drug and Extract, C and D = Scar Creation and E = Rabbit Ear Scar Development



Plate II: Wounding of rabbit ear to the dermis to create scar (1); Using ultrasound in monitoring of scar progress in rabbit (2); Progress of scar during dermal administration of extracts, a = post-wound 1 week, b = post-wound 2 weeks, c and d = post-wound 3 weeks, e and f = post-wound 4 weeks (3)

Discussion

Musa cavendishii peels have been used traditionally in the management of many illnesses like wound healing, ulcers and scars. These are due to a report linking these activities to the presence of antioxidants such as vitamin C and E and phenolic compounds (Espinosa and Santacruz, 2017). The LD_{50} of the extracts was found to be greater than 5000 mg/kg, dermally in New Zealand rabbits during the acute toxicity study which provided an initial evidence of the potential safety of the extracts and this agreed with the work of Ugbogu, 2018. The present study seeks to evaluate the antihypertrophic scar activity of *Musa cavendishii* peel extracts using ultrasonography.

An ultrasound device has the main component called transducer which has a material (usually piezoelectric crystals) that generates acoustic waves when subjected to an electric voltage (Bagatin *et al*., 2013). This wave propagates in fluid and/or surrounding tissue and the echoes reflected by these structures return to the transducer, which transforms them into electrical energy. Thus, the transducer is the element that transforms electrical energy into mechanical acoustic wave and makes the reverse process when receiving the echoes, being the transmitter and the receiver component (Wortsman, 2013). The electrical energy, after being processed by the computer, causes the formation of an image view at the monitor. This is represented on the screen by luminous points that vary in intensity according to the degree of reflection of different structures that the sound beam crosses. The ability of the ultrasound scan transducer used in this work to visualized the hyper-echogenic area of scar even before the administration of the extracts and the standard drug correlate with the work of Bagatin *et al*., 2013 that the transducer can generate acoustic waves when subjected to an electrical voltage. This ability is what makes ultrasound scanner an excellent method for assessing edges and interface between different regions (Kleinerman *et al*., 2012).

In two-dimensional-ultrasound (B-mode) which was the exact ultrasound used in this work, the brightness of each pixel corresponds to the amplitude of the echo (Marmur *et al*., 2010). The intensity of the echoes in the image is called echogenicity. Images with high intensity echoes are called echogenic or hyper-echoic; those with low intensity are called hypo-echoic; and the ones without echoes that is black, anechoic or echolucent. What determines the echogenicity of each tissue is the speed at which the sound wave can pass through it and the quantity and intensity of echoes returned to the device. In normal skin, the echogenicity of each layer depends on its main component that is, in the epidermis, it is the keratin; in the dermis, it is the collagen; and in subcutaneous tissue, are the fat lobules (Barcaui *et al*., 2015). The interval between the emitted and reflected waves allows calculating the distance between the reflected structures. In this work, the hyper-echoic region visualized within the skin where wound was excised as compared to the skin closed to the excised wound and that of distilled water signified the scar region. Also the morphological changes within the week interval which are noticed by decreased in the length and area of the scar area signified that the aqueous extract especially at the high doses of 2000 and 5000 mg/kg body weight has antihypertrophic scar property which can be measured conveniently using high frequency ultrasound scan. This work is in agreement with the work of Moawia, (2018) who used ultrasound to evaluate the morphological changes of transplanted kidneys in Sudanese patients.

The images in ultrasound especially when measuring lesion are obtained in vertical sections and both the resolution and penetration vary according to the frequency of the ultrasound machine (Ulrich *et al*., 2007). The higher the frequency, the shorter the wavelength that reaches the tissues: better resolution with less penetration. In scar monitoring especially in this work, high resolution Sono-star ultrasound devices with high frequency transducers are used and this provide better assessment of the scar in the different group with different doses of extract hence visualization of lesion beneath the epidermis and dermis in the skin are perfectly seen which correlate with work of Ruiqian *et al*., (2020).

Scar monitoring during dermal applications of drugs demand an accurate quantitative and noninvasive analysis of the lesion, but at present, there is no reliable assessment tool for measuring the characteristics in length, diameter and area of cutaneous scars (Perry *et al*., 2010). Although ultrasonography is a technique that can be conveniently used in daily practice and had demonstrated a good basic accuracy and reliability in scar management and monitoring (Li *et al*., 2013). Ultrasound as used in this study, results in monitoring of scar reduction from the different doses of the extracts and standard drug, triamcinolone acetonide, topical (0.1 %). In this work, the ultrasound scan was able to monitor the scar regression without causing any complications to the wounded area of the rabbits which agreed with the work of Aya *et al*., 2014 who used ultrasound elastographic methods which provided the means for the objective and noninvasive evaluation of the stiffness of organs, such as the liver, breast, and thyroid.

The Vancouver scar scale scores (VSS) is use to evaluate the risk factors for the development of hypertrophic scar (HTS) and to assess the effectiveness of treatment of scar, although raised scar height is the defining feature of hypertrophic scar (Tyack *et al*., 2012). The entire VSS score serves as a greatest accuracy in diagnosing hypertrophic scar. Clinicians and researchers can easily use it to reach a consensus in their opinions about what a score on the VSS can constitutes HTS with comparing it with other measurement scale (ultrasound scanner) of measuring scar. In this work, the thread used in measuring the length and height of the hypertrophic scar at the initial point before translating it to ruler for accurate measurement give a firsthand information when correlating it with that of the ultrasound results. All other VSS parameter in this work are in agreement with the work of Thompson *et al*., (2015) but disagree with the work of Tyack *et al*., (2012) which only believed that VSS is used as a risk factors for the development of hypertrophic scar without using thread in assessing the height and the length of such scar.

In summary, this technique allows the noninvasive and examination of hypertrophic scars providing an innocuous way to objectively visualize the dynamics of the lesions while undergoing different therapeutic approaches. The use of an ultrasound to measure scar thickness after treatment with different doses of plant extracts therapy is reproducible, readily available and can feasibly be integrated into a pharmacological study to monitor hypertrophic scar.

Conclusion

In the duration of 30 days monitoring of antihypertrophic scar activity of *Musa cavendishii* peel extracts, the ultrasound scan shows changes in the morphology, hyper-echogenicity of the scar and as well as changes in the diameter, length and area of the scar. This change serves as a useful and

important tool to predict the outcome of a scar reduction when administrating *Musa cavendishii* peel extracts.

Conflicts of interest

There are no conflicts of interest regarding this study

Funding

Nil

References

Abubakar A, Ibrahim H, Yusuf KM, Iliya I, Suleiman MM, and Eloff NJ. (2019) Antioxidant properties of extracts from *Tacazzea speculate* Oliv. (Periplocaceae) FUW *Trends Sci Tech*; 4(1):075–7.

Adebayo JO. and Krettli AU. (2011). "Potential antimalarials from Nigerian plants: a review," *J of Ethnopharm*, 133(2): 289–302.

Aya R, Yamawaki S, Muneuchi G, Naitoh M. and Suzuki S. (2014). Ultrasound elastography to evaluate keloids. *Plastic and reconstructive surgery. Global open*, *2*(2), e106. https://doi.org/10.1097/GOX.0000000000000048

Bagatin E, Caetano LVN. and Soares JLM. (2013). Ultrasound and dermatology: basis principles and main applications in dermatologic research. Expert Rev of Dermatol. 8:463–477

Barcaui EO, Carvalho ACP, Piñeiro-Maceira J, Barcaui CB. and Morae H (2015). Estudo da anatomia cutânea com ultrassom de alta frequência (22MHz) e sua correlação histológica. Radiol Bras;48:324–329

Bessonarta MN, Macedo N. and Carmona C. (2005). High resolution B-scan ultrasound of hypertrophic scars. Skin Res Technol; 11:185–188.

Cao C, Li SR, Dai X., *et al*., (2009). "Genistein inhibits proliferation and functions of hypertrophic scar fibroblasts," *Burns*, 35(1): 89–97.

Espinosa, Alfredo and Santacruz S. (2017). Phenolic compounds from the peel of *Musa cavendishii, Musa acuminata and Musa cavandanaish.*. Revista Politécnica – Enero; 38,2.

George NR, Siordia NH, Buhler NJ, Thompson NS, Cancio L. and Can R. (2019). 315 The Use of High Frequency Ultrasound to Monitor Treatment of Hypertrophic Burn Scars with Fractionated Ablative CO2 Laser Therapy. *Journal of Burn Care & Research*. 40:135

Jurzak M. and Adamczyk K. (2013). "Influence of genistein on c-jun, cfos and fos-b of ap-1 subunits expression in skin keratinocytes, fibroblasts and keloid fibroblasts cultured in vitro," *Acta Poloniae Pharmaceutica*; 70(2): 205–213

Kleinerman R, Whang TB, Bard RL. and Marmur ES (2012). Ultrasound in dermatology. Principles and applications. J Am Acad Dermatol;67:478–487

Lee HJ. and Jang YJ. (2018). Recent Understandings of Biology, Prophylaxis and Treatment Strategies for Hypertrophic Scars and Keloids. *Int. J. Mol. Sci. 19*, 711

Li JQ, Li-Tsang CW, Huang YP. *et al*., (2013). Detection of changes of scar thickness under mechanical loading using ultrasonic measurement. Burns;39: 89–97

Marmur ES, Berkowitz EZ, Fuchs BS, Singer GK, Yoo JY (2010). Use of high frequency, high resolution ultrasound before Mohs surgery. Dermatol Surg; 36:841–847

Moawia Gameraddin, (2018). Ultrasound evaluation of morphological changes of transplanted kidneys in Sudanese patients. A J Diagn Imaging;3 (1): 1-6

Morris DE, Wu L, Zhao LL. *et al*., (1997). "Acute and chronic animal models for excessive dermal scarring: quantitative studies," *Plastic and Reconstructive Surgery*; 100(3):674–681

OECD (2017) Guideline for Testing of Chemicals. Fixed Dose Procedure 14-Days Acute Dermal Toxicity Study in Rodents. Paris, France: Organisation for Economic Co-operation and Development

Perry DM, McGrouther DA. and Bayat A. (2010). Current tools for noninvasive objective assessment of skin scars. Plast Reconstr Surg; 126: 912–923

Rittie and Laure (2017). Method in Molecular Biology, Fibrosis, Volume 1627, Hypertrophic Scarring in the Rabbit Ear: A Practical Model for Studying Dermal Fibrosis: A practical model for studying dermal fibrosis; 10.1007/978-1-4939-7113-8(Chapter 6), 81–89. doi:10.1007/978-1-4939-7113-8

Ruiqian Guo, Xi Xiang, Liyun Wang, Bihul Zhu, Shan Cheng, Li Qiu (2020). Quantitative Assessment of keloids using ultrasound shear waved elastography. Ultrasmedbio

Sheidu AR, Maiha BB, Magaji MG. and Ahmed A. (2021). Successive solvent extraction, phytochemical screening, and thin layer chromatography profiling of *Musa cavendishii* Linn peel.Science Forum (*J. of Pure and Applied Sci.*); 21:192 – 200

Thompson CM, Sood RF, Honari S, Carrougher GJ. and Gibran NS. (2015). What score on the Vancouver Scar Scale constitutes a hypertrophic scar? Results from a survey of North American burn-care providers. *Burns*, 41, 1442-1448.

Tracy LE, Minasian RA. and Caterson EJ. (2016). Extracellular Matrix and Dermal Fibroblast Function in the Healing Wound. Adv Wound Care (New Rochelle); 5(3):119-136

Tyack Z, Simons M, Spinks A. and Wasiak JA. (2012) systematic review of the quality of burn scar rating scales for clinical and research use. Burns;38:6–18

Ugbogu EA, Ude VC, Elekwa I, Arunsi UO, Uche-Ikonne C. and Nwakanma C. (2018). Toxicological profile of the aqueous-fermented extract of *Musa paradisiaca* in rats. *Avicenna journal of phytomedicine*, *8*(6):478–487.

Ulrich M, Stockfleth E, Roewert-Huber J. and Astner S. (2007). Noninvasive diagnostic tools for nonmelanoma skin cancer. Br J Dermatol;157:56–58

Wortsman X. (2013). Ultrasound in dermatology: why, how, and when? Semin Ultrasound CT MR; 34:177–195